

Corneal Changes After Small-Incision Cataract Surgery in Patients With Diabetes Mellitus

Soichi Morikubo, MD; Yoshihiro Takamura, MD, PhD; Eri Kubo, MD, PhD; Shosai Tsuzuki, MD, PhD; Yoshio Akagi, MD, PhD

Objective: To evaluate functional impairment in the corneal endothelium of eyes in patients with diabetes mellitus, after small-incision cataract surgery.

Methods: Evaluation was performed in 93 eyes in patients with type 2 diabetes mellitus (diabetic group) and 93 eyes in patients without diabetes mellitus (nondiabetic group) who underwent cataract surgery. Using a topography system, the corneal thickness in the central area was measured before surgery and 1 day, 1 week, and 1 month after surgery. Corneal endothelial cells were counted using a noncontact specular microscope.

Results: No significant differences in any preoperative measures were observed between the diabetic and non-

diabetic groups. The increase in corneal thickness 1 month after surgery was significantly higher in the diabetic group than in the nondiabetic group ($P=.03$). The corneal endothelial cell losses 1 day and 1 week after surgery were significantly higher in the diabetic group than in the nondiabetic group (after 1 day, $P=.03$; and after 1 week, $P=.04$).

Conclusion: Compared with nondiabetic eyes, eyes of patients with diabetes mellitus showed more damage in corneal endothelial cells due to cataract surgery and a delay in the postoperative recovery of corneal edema.

Arch Ophthalmol. 2004;122:966-969

IN RECENT YEARS, ADVANCES HAVE been made in cataract surgery because of improvement in surgical equipment, viscoelastic agents, and techniques, expanding the indications for this surgery. After the development of phacoemulsification, corneal endothelial damage was not an absolute contraindication for cataract surgery. However, bullous keratopathy induced by mechanical injury in the corneal endothelium is intractable; therefore, preoperative evaluation of endothelial tissue is important.

Corneal damage is often encountered after intraocular surgery in patients with diabetes mellitus. Based on this finding, fragility of the cornea in patients with diabetes mellitus has been suggested.¹⁻³ In general, the cornea of patients with type 1 diabetes mellitus shows morphological abnormalities of endothelial cells (polymegethism and pleomorphism),⁴⁻¹¹ but normal barrier function as represented by fluorescein permeability.^{8,9,12} In addition, although corneal edema induced by contact lens wear is similar in diabetic and nondiabetic groups, corneal edema recovery is slower in patients with diabetes mellitus than in control subjects.^{13,14} This suggests that the cornea in patients with diabe-

tes mellitus is weaker than the normal cornea against physical stress. In contrast, Weston et al¹⁵ reported that induced swelling was less in patients with diabetes mellitus than in controls, and the corneal deswelling rate was not different between diabetic and control subjects. Therefore, in the present study, we evaluated functional impairment in the corneal endothelium of eyes of patients with diabetes mellitus after small-incision cataract surgery.

METHODS

Evaluation was performed in 93 eyes in patients with type 2 diabetes mellitus (diabetic group) and 93 eyes in patients without diabetes mellitus (nondiabetic group) who underwent cataract surgery (phacoemulsification and intraocular lens implantation) at our division between March 15, 2000, and June 20, 2002. The nondiabetic group was selected randomly, and both groups were age-matched. Written informed consent was obtained from all patients before surgery and examinations, and the study was approved by an ethics committee. The mean \pm SD age was 68.8 ± 8.9 years in the nondiabetic group and 68.6 ± 8.8 years in the diabetic group (**Table**). Because the cornea was evaluated, patients with corneal disorder or history of ocular operation, contact lens wear, and ocular injury were excluded. Surgery was per-

From the Division of Ophthalmology, School of Medicine, Fukui University, Fukui, Japan. The authors have no relevant financial interest in this article.

Preoperative Data*

Preoperative Value	Nondiabetic Group (n = 93)	Diabetic Group			
		Overall (N = 93)	No Retinopathy (n = 34)	Simple Retinopathy (n = 36)	Proliferative Retinopathy (n = 23)
Age, y	68.8 ± 8.9	68.6 ± 8.8	69.1 ± 10.2	70.4 ± 5.2	67.1 ± 9.3
Corneal thickness, μm	541.9 ± 33.3	544.0 ± 37.2	536.5 ± 40.8	548.5 ± 37.5	545.5 ± 35.6
Endothelial cell density, per mm ²	2721.6 ± 348.1	2727.9 ± 404.0	2696.6 ± 452.7	2740.2 ± 293.2	2726.7 ± 422.2
Coefficient of variation	0.306 ± 0.066	0.314 ± 0.072	0.321 ± 0.063	0.304 ± 0.081	0.311 ± 0.075
Hexagonal cells, %	58.8 ± 10.4	57.7 ± 13.2	54.5 ± 12.1	60.2 ± 17.4	60.0 ± 12.1

*Data are given as mean ± SD.

formed by 4 experienced surgeons, who had performed cataract surgery in more than 500 cases. There were no differences between the 2 study groups in phacoemulsification time and intraocular infusion volume.

Cataract surgery was performed under Tenon anesthesia. A nonsuture sclerocorneal incision (3.5 mm from the 12-o'clock position) was made, and continuous curvilinear capsulorrhexis was performed, using Healon (Pharmacia, Uppsala, Sweden) as a viscoelastic agent. The nucleus was divided by the phaco-chop method, and phacoemulsification and aspiration were performed. For cataract surgery, Accurus (Alcon Laboratories, Inc, Fort Worth, Tex) equipment was used, and BSS PLUS (Alcon Laboratories, Inc) was the perfusion fluid used. After cortical aspiration, an acryl-foldable intraocular lens (Acrysof MA60BM; Alcon Laboratories, Inc) was inserted.

The corneal thickness in the central area was measured using the ORBSCAN topography system (ORBTEK; Bausch & Lomb, Rochester, NY) before surgery and 1 day, 1 week, and 1 month after surgery. Corneal endothelial cells were counted using a noncontact specular microscope, NONCON ROBO (Konan Medical, Inc, Hyogo, Japan). These examinations were performed in a masked manner by one technician (S.M.).

The items evaluated in this study were central corneal thickness (in micrometers), endothelial cell density (cells per square millimeter), percentage of hexagonal cells, and the coefficient of variation before and after operation. Changes in each item after operation were compared between the diabetic and nondiabetic groups by *t* test.

RESULTS

Before cataract operation, the age-matched nondiabetic group had a mean ± SD central corneal thickness of 541.9 ± 33.3 μm, corneal endothelial cell density of 2721.6 ± 348.1 cells/mm², coefficient of variation of 0.306 ± 0.066, and 58.8% ± 10.4% hexagonal cells. The diabetic group had a mean ± SD central corneal thickness of 544.0 ± 37.2 μm, corneal endothelial cell density of 2727.9 ± 404.0 cells/mm², coefficient of variation of 0.314 ± 0.072, and 57.7% ± 13.2% hexagonal cells. No significant difference was observed in any preoperative item measured between the diabetic and nondiabetic groups. In addition, in the diabetic group, central corneal thickness, endothelial cell density, coefficient of variation, and percentage of hexagonal cells were not significantly associated with the severity of diabetic retinopathy (Table).

Serial changes in the increase in central corneal thickness after operation are shown in **Figure 1**. Compared with the preoperative thickness, increases observed 1 day, 1 week, and 1 month after operation were 4.2%, 0.9%, and 0.04%, respectively, in the nondiabetic group and 3.9%,

1.6%, and 1.6%, respectively, in the diabetic group. The increase after 1 month was significantly higher in the diabetic group than in the nondiabetic group (*P* = .03).

Serial changes in endothelial cell loss after operation are shown in **Figure 2**. The endothelial cell losses occurring 1 day, 1 week, and 1 month after operation were 2.1%, 3.6%, and 3.2%, respectively, in the nondiabetic group and 7.0%, 7.9%, and 7.2%, respectively, in the diabetic group. Endothelial cell losses occurring after 1 day and 1 week were significantly higher in the diabetic group than in the nondiabetic group (after 1 day, *P* = .03; and after 1 week, *P* = .04).

The coefficients of variation 1 day, 1 week, and 1 month after operation were 0.334, 0.316, and 0.308, respectively, in the nondiabetic group and 0.331, 0.314, and 0.312, respectively, in the diabetic group, without significant differences between the 2 groups (**Figure 3**).

The percentages of hexagonal cells 1 day, 1 week, and 1 month after operation were 56.7%, 57.7%, and 57.2%, respectively, in the nondiabetic group and 53.3%, 55.6%, and 55.7%, respectively, in the diabetic group, without significant differences between the 2 groups (**Figure 4**).

COMMENT

Corneal endothelial abnormalities in diabetic patients have been reported.⁴⁻¹¹ However, these are morphological abnormalities, such as polymegethism and pleomorphism, and do not include abnormal permeability. Studies^{4,5,7-9} have found no significant differences in the endothelial cell density between eyes of patients with and without diabetes mellitus. The cornea has been reported to be thicker in eyes of diabetic patients than in eyes of nondiabetic subjects by some authors^{9,10} but shown to be similar by others.^{6,9} Roszkowska et al¹⁰ demonstrated that the cornea in diabetic patients is significantly thicker than the cornea in nondiabetic subjects, speculating that the pump function of the corneal endothelium is decreased, resulting in edema against osmotic pressure in eyes of diabetic patients. On the other hand, no association between corneal thickness and retinopathy or diabetic control has been reported.^{7,11} In this study, the mean thickness of the central cornea before operation was slightly thicker in the diabetic group (544.0 μm) than in the nondiabetic group (541.9 μm), but the endothelial cell density, coefficient of variation, and percentage of hexagonal cells did not significantly differ between the 2 groups. However, because cataract surgery was indicated in both groups in this study, the results cannot be

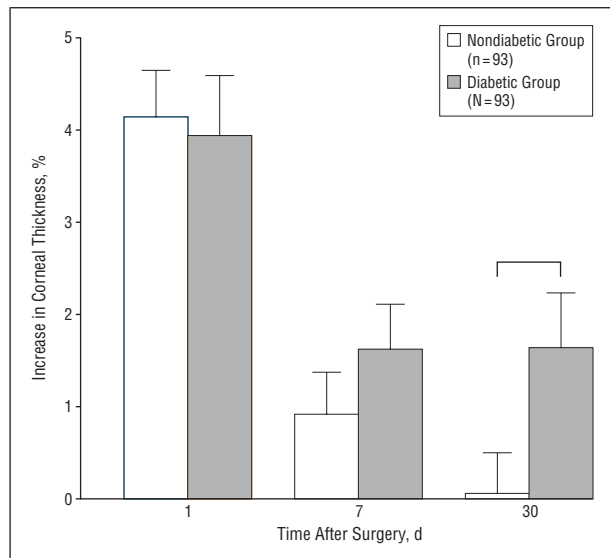


Figure 1. The increase in corneal thickness after 1 month was significantly higher in the diabetic group than in the nondiabetic group ($P=.03$).

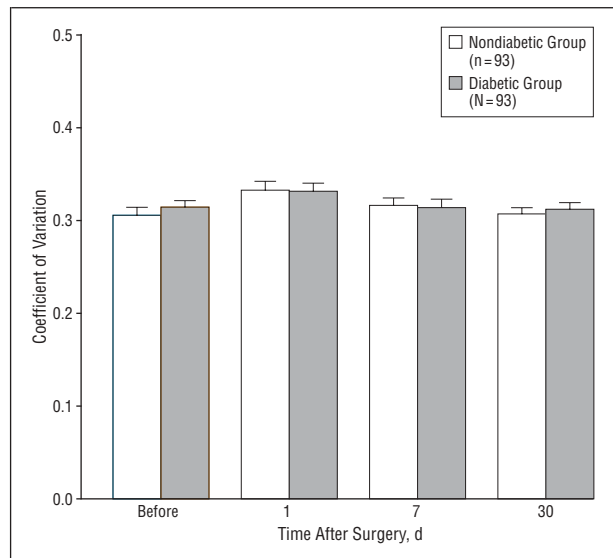


Figure 3. The coefficients of variation 1 day, 1 week, and 1 month after operation were not different in the diabetic and nondiabetic groups.

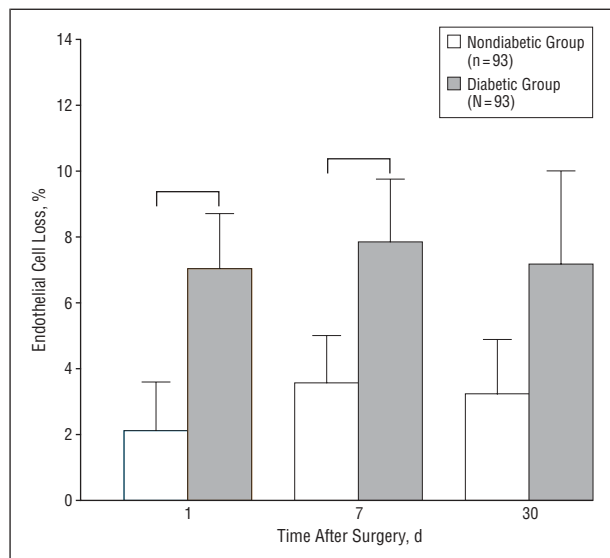


Figure 2. The endothelial cell losses occurring 1 day and 1 week after surgery were significantly higher in the diabetic group than in the nondiabetic group (after 1 day, $P=.03$; and after 1 week, $P=.04$).

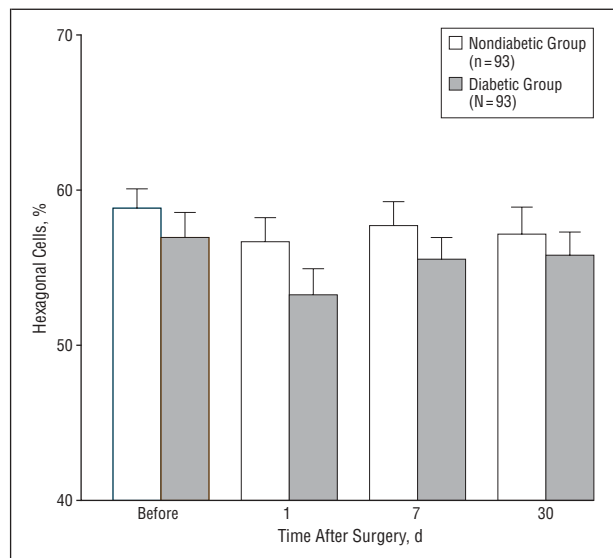


Figure 4. The percentages of hexagonal cells 1 day, 1 week, and 1 month after operation were not different in the diabetic and nondiabetic groups.

directly compared with those of other studies that assessed diabetic and nondiabetic groups irrespective of surgical indications.

Concerning postoperative changes, the increase in central corneal thickness was highest 1 day after operation among the 3 time points measured in the diabetic and nondiabetic groups, but recovered thereafter. However, the recovery rate was slow in the diabetic group compared with the nondiabetic group. The increase in central corneal thickness 1 month after operation was 0.04% in the nondiabetic group and 1.6% in the diabetic group, showing significantly poor recovery in the latter. Therefore, recovery of corneal edema after cataract surgery may be delayed in the cornea of diabetic patients, as the corneal thickness will not have returned to the preoperative level 1 month after surgery.

Previous studies¹⁶⁻¹⁸ have shown that endothelial cell density decreases 6% to 10% after phacoemulsification for cataract. In this study, the decrease in endothelial cells was maximal 1 week after operation among the 3 time points measured in the diabetic and nondiabetic groups. The endothelial cell losses 1 day and 1 week after operation were significantly greater in the diabetic group (7.0% and 7.9%, respectively) than in the nondiabetic group (2.1% and 3.6%, respectively). Based on these results, we speculated that the corneal endothelium in diabetic patients is under metabolic stress, and weaker against mechanical loads, such as cataract surgery, than that in nondiabetic subjects.

The percentage of hexagonal cells decreased after 1 day and was slightly lower in the diabetic group than in the nondiabetic group at each measurement point. The coefficient of variation slightly increased 1 day after operation, but did

not significantly differ between the 2 groups. The corneal endothelium, once decreased, does not proliferate, and the defects are covered by stretching, extension, and transfer of the residual corneal endothelium.¹⁹ Although we considered that the coefficient of variation and percentage of hexagonal cells can be indexes of the repair mechanism, no marked difference was observed in either variable between the diabetic and nondiabetic groups in this study.

Goebbels and Spitznas¹² performed fluorophotometry of the corneal endothelium before and 4 days, 3 weeks, and 6 weeks after phacoemulsification and intraocular lens implantation, and endothelial permeability was evaluated in the presence or absence of diabetes mellitus. Endothelial permeability did not differ between the diabetic and nondiabetic groups before operation, markedly increased in both groups 4 days after operation, and recovered 3 weeks after operation in the nondiabetic group but 6 weeks after operation in the diabetic group. This result was consistent with the delayed recovery of endothelial function in the cornea of diabetic patients after cataract surgery observed in our study. On the other hand, Furuse et al²⁰ compared the endothelial cell density, coefficient of variation, and endothelial cell loss 3, 6, and 12 months after extracapsular cataract extraction and intraocular lens implantation between patients with and without diabetes mellitus and observed endothelial cell density decreases of 10% to 20% in both groups, without noticeable differences. This variation in findings between their study and ours may be because extracapsular cataract extraction is more invasive to the cornea than phacoemulsification and masks diabetes mellitus-associated differences.

One theory that can explain the fragility of the corneal endothelium in eyes of diabetic patients is the polyol osmotic theory.²¹⁻²⁴ In diabetic patients, the polyol pathway is enhanced, and excessive glucose is converted to sugar alcohol, which accumulates in cells. Aldose reductase in the polyol pathway is distributed in the corneal epithelium and endothelium.^{25,26} Accumulation of sugar alcohol may induce hyperosmolality, causing corneal endothelial fragility. Morphological abnormalities in the corneal endothelium have been reported to improve after administration of an inhibitor of this enzyme,^{27,28} which supports the involvement of this enzyme in the development of corneal endothelial abnormalities in eyes of patients with diabetes mellitus.

CONCLUSIONS

Compared with nondiabetic eyes, eyes of diabetic patients showed more damage in corneal endothelial cells after cataract surgery and a delay in the postoperative recovery of corneal edema. This suggests that eyes of diabetic patients may be under metabolic stress and have corneal endothelium with lower reserve ability than nondiabetic eyes. Although normal corneal stability is maintained by the reserve function of corneal endothelial cells, surgical invasion destroys reserve ability, resulting in delay in postoperative recovery of corneal edema compared with nondiabetic eyes. Because of advances in small-incision cataract surgery, severe corneal edema rarely develops, but the protection of the corneal endothelium is important for long-term corneal function after intraocular surgery in eyes of diabetic patients.

Submitted for publication August 4, 2003; final revision received December 9, 2003; accepted January 9, 2004.

Correspondence: Yoshio Akagi, MD, PhD, Division of Ophthalmology, School of Medicine, Fukui University, 23 Shimoaizuki, Matsuoka, Fukui 910-1193, Japan (akagi@fmsrsa.fukui-med.ac.jp).

REFERENCES

- Fouls GN, Thoft RA, Perry HD, Tolentino FI. Factors related to corneal epithelial complications after closed vitrectomy in diabetics. *Arch Ophthalmol*. 1979;97:1076-1078.
- Brightbill FS, Myers FL, Bresnick GH. Postvitrectomy keratopathy. *Am J Ophthalmol*. 1978;85:651-655.
- Perry HD, Fouls GN, Thoft RA, Tolentino FI. Corneal complications after closed vitrectomy through the pars plana. *Arch Ophthalmol*. 1978;96:1401-1403.
- Schultz RO, Matsuda M, Yee RW, Edelhauser HF, Schultz KJ. Corneal endothelial changes in type I and type II diabetes mellitus. *Am J Ophthalmol*. 1984;98:401-410.
- Yee RW, Matsuda M, Kern TS, Engerman RL, Edelhauser HF. Corneal endothelial changes in diabetic dogs. *Curr Eye Res*. 1985;4:759-766.
- Itoi M, Nakamura T, Mizobe K, Kodama Y, Nakagawa N, Itoi M. Specular microscopic studies of the corneal endothelia of Japanese diabetics. *Cornea*. 1989;8:2-6.
- Matsuda M, Ohguro N, Ishimoto I, Fukuda M. Relationship of corneal endothelial morphology to diabetic retinopathy, duration of diabetes and glycemic control. *Jpn J Ophthalmol*. 1990;34:53-56.
- Keoleian GM, Pach JM, Hodge DO, Trocme SD, Bourne WM. Structural and functional studies of the corneal endothelium in diabetes. *Am J Ophthalmol*. 1992;113:64-70.
- Larsson LI, Bourne WM, Pach JM, Brubaker RF. Structure and function of the corneal endothelium in diabetes mellitus type I and type II. *Arch Ophthalmol*. 1996;114:9-14.
- Roszkowska AM, Tringali CG, Colosi P, Squeri CA, Ferreri G. Corneal endothelium evaluation in type I and type II diabetes mellitus. *Ophthalmologica*. 1999;213:258-261.
- Inoue K, Kato S, Inoue Y, Amano S, Oshika T. The corneal endothelium and thickness in type II diabetes mellitus. *Jpn J Ophthalmol*. 2002;46:65-69.
- Goebbels M, Spitznas M. Endothelial barrier function after phacoemulsification: a comparison between diabetic and non-diabetic patients. *Graefes Arch Clin Exp Ophthalmol*. 1991;29:254-257.
- Herse P, Hooker B. Corneal edema recovery dynamics in diabetes: is the alloxan induced diabetic rabbit a useful model? *Invest Ophthalmol Vis Sci*. 1994;35:310-313.
- Saini JS, Mittal S. In vivo assessment of corneal endothelial function in diabetes mellitus. *Arch Ophthalmol*. 1996;114:649-653.
- Weston BC, Bourne WM, Polse KA, Hodge DO. Corneal hydration control in diabetes mellitus. *Invest Ophthalmol Vis Sci*. 1995;36:586-595.
- Diaz-Valle D, Benitez del Castillo Sanchez JM, Castillo A, Sayagues O, Moriche M. Endothelial damage with cataract surgery techniques. *J Cataract Refract Surg*. 1998;24:951-955.
- Walkow T, Anders N, Klebe S. Endothelial cell loss after phacoemulsification: relation to preoperative and intraoperative parameters. *J Cataract Refract Surg*. 2000;26:727-732.
- Dick HB, Kohnen T, Jacobi FK, Jacobi KW. Long-term endothelial cell loss following phacoemulsification through a temporal clear corneal incision. *J Cataract Refract Surg*. 1996;22:63-71.
- Matsuda M, Sawa M, Edelhauser HF, Bartels SP, Neufeld AH, Kenyon KR. Cellular migration and morphology in corneal endothelial wound repair. *Invest Ophthalmol Vis Sci*. 1985;26:443-449.
- Furuse N, Hayasaka S, Yamamoto Y, Setogawa T. Corneal endothelial changes after posterior chamber intraocular lens implantation in patients with or without diabetes mellitus. *Br J Ophthalmol*. 1990;74:258-260.
- Cogan DG, Kinoshita JH, Kador PF, et al. NIH conference: aldose reductase and complications of diabetes. *Ann Intern Med*. 1984;101:82-91.
- Kinoshita JH. Mechanisms initiating cataract formation: Proctor Lecture. *Invest Ophthalmol*. 1974;13:713-724.
- Kador PF. The role of aldose reductase in the development of diabetic complication. *Med Res Rev*. 1988;8:325-352.
- Kinoshita JH, Nishimura C. The involvement of aldose reductase in diabetic complication. *Diabetes Metab Rev*. 1988;4:323-337.
- Akagi Y, Yajima Y, Kador PF, Kuwabara T, Kinoshita JH. Localization of aldose reductase in the human eye. *Diabetes*. 1984;33:562-566.
- Kern TS, Engerman RL. Distribution of aldose reductase in ocular tissues. *Exp Eye Res*. 1981;33:175-182.
- Ohguro N, Matsuda M, Ohashi Y, Fukuda M. Topical aldose reductase inhibitor for correcting corneal endothelial changes in diabetic patients. *Br J Ophthalmol*. 1995;79:1064-1065.
- Matsuda M, Awata T, Ohashi Y, Inaba M, Fukuda M, Manabe R. The effects of aldose reductase inhibitor on the corneal endothelial morphology in diabetic rats. *Curr Eye Res*. 1987;6:391-397.