

MAJOR REVIEW

Hypopyon Uveitis

Andrew Ramsay, BSc, FRCOphth, and Susan Lightman, PhD, FRCP, FRCOphth, FMedSci

Uveitis Clinic, Moorfields Eye Hospital, London, United Kingdom

Abstract. Hypopyon uveitis has inflammatory, infective, and neoplastic causes and a high association with systemic disease. Careful questioning of the patient and detailed examination of the eye for other signs is necessary to guide the differential diagnosis and relevant investigations. Because the underlying causes require very different types of investigation and, if missed, can have serious sequelae for the patient, a rational approach based on the understanding of the causes of hypopyon uveitis is imperative. In this review, hypopyon uveitis is considered in the context of the associated ocular and systemic diseases that cause it. (*Surv Ophthalmol* 46:1–18, 2001. © 2001 by Elsevier Science Inc. All rights reserved.)

Key words. Behcet's disease • endophthalmitis • HLA-B27 • hypopyon • keratitis • pseudohypopyon • uveitis

Hypopyon is sediment forming in the dependent part of the anterior chamber. It occurs in association with intraocular inflammation, infection, or malignancy, as well as keratitis. It is of value as a clinical sign, because it tends to occur in association with specific conditions rather than as a general ocular inflammatory response. Provided the significance of this simple clinical sign is recognized, its associated conditions can be promptly diagnosed and treated.

I. Definitions

By the strictest definition, *hypopyon* is the accumulation of pus resulting from suppurative infection inferiorly in the anterior chamber. However, hypopyon may be neither caused by infection nor lie at 6 o'clock in the anterior chamber. Firstly, hypopyon caused by inflammatory mechanisms does not contain microorganisms. If hypopyon is due to ocular tumors, it consists largely of neoplastic cells, in which case the term *pseudohypopyon* is often used. However, in the clinical setting, the appearances are identical and therefore pseudohypopyon will be discussed with hypopyon. Secondly, hypopyon collects

at the dependent part of the anterior chamber, so after a shift in posture it may either be dispersed or in a different orientation. The speed with which it settles again will vary according to the content of the material.¹³⁵ Finally, *macrohypopyon* refers to hypopyon visible to the naked eye, whereas *microhypopyon* refers to hypopyon visible only microscopically. *Angle-hypopyon* is a subcategory of microhypopyon visible in the dependent anterior chamber angle only on gonioscopy. The prevalence of hypopyon may, therefore, vary among clinical series if the stringency of diagnostic criteria for this clinical sign differ.

II. Pathology

During the acute exudative phase of inflammation, the anterior chamber may be either serous protein, as in aqueous "flare," fibrinous ("plastic") exudate, or purulent, as in hypopyon. Hypopyon in both intraocular infection and inflammation consists largely of tissue debris, inflammatory by-products and recruited leukocytes.¹¹⁹ Hematoxylin and eosin staining of hypopyon reveals a dense purplish mass containing dead and dying polymorphs

(PMNs) in various stages of disintegration, simplified proteins, nucleoproteins, lipids, and fluids, together with both necrotic and living remains of tissue cells.¹¹⁹

PMNs are among the first and most active cells in the acute inflammatory reaction. They phagocytose and degrade bacteria, dead cells, collagen fibers, and serum proteins, such as fibrin, by ingestion and fusion of the phagosome with lysosomes. Lysosomes contain specific granules containing microbicidal lysozyme, lactoferrin, and azurophilic lysosomal granules containing enzymes (phosphatases, myeloperoxidase, nucleases, nucleotidase, lysozyme, cathepsin, beta-glycuronidase, collagenase, elastase, kallikrein, plasminogen). In hypopyon secondary to intraocular infection, both viable and nonviable organisms may be found.

In view of the presence of large numbers of tumor cells in the anterior chamber in tumor-associated hypopyon, the term *pseudohypopyon* is used once the diagnosis is established.^{17,63} This term has also been used to describe the appearance of Best's vitelliform macular dystrophy.¹¹⁰ The location and friability of the neoplastic deposits influence the development of a pseudohypopyon. Leukemic deposits in the iris, for example, are friable and can gain easy access to the anterior chamber, whereas posterior segment or more slowly growing tumors are spatially and structurally separated and rarely produce hypopyon.

Hypopyon associated with corneal disorders are sterile, with the exception of fungal keratitis, in which live fungi may penetrate Descemet's membrane and enter the anterior chamber.

III. Pathogenesis

There is no single unifying process by which hypopyon forms. Initiating factors include infection, cellular immune reactions influenced by patterns of

HLA expression, and trauma.¹⁵¹ Exposure to gram-negative organisms has been implicated as a causative factor in some HLA-B27 patients with uveitis,^{201,220} so it is possible that hypopyon associated with infection and uveitis share the same trigger.

In all cases, the development of hypopyon depends upon the strength of local chemotactic and activating stimuli and the degree of tissue destruction engendered by the inflammatory process concerned. Chemotaxins are derived from bacterial material, injured tissue, plasma (e.g., complement system) and PMNs. Of the leukotrienes, LTB₄ is the most important PMN-chemotaxin, and it is responsible for the arrival of large numbers of PMNs. Local vascular damage and the vasodilatory influence of bradykinin—which is derived from plasma by the action of kallikrein and histamine from platelets, basophils, and mast cells—allows exudation of PMNs, necrotic debris, and inflammatory mediators into the anterior chamber from iris vessels.

In infective hypopyon the alternative complement pathway is a ubiquitous first line of defense against microbes. It is activated by bacterial endotoxin, or polysaccharide, or by PMN lysosomal enzymes. C3a, C5a, and the activated complex of C5, C6, and C7 are strongly chemotactic for PMNs. C8 and C9 lyse cells and bacterial membranes. Activation of PMNs in infectious disease aids phagocytic clearance of microbes. PMNs frequently appear degenerate because they turn over very quickly anyway and are also killed by exotoxins released by certain bacteria. However, PMNs are also activated in hypopyon-iridocyclitis.^{50,94} Anterior chamber cells from a patient with hypopyon uveitis associated with psoriasis and arthropathy were found to be activated, as judged by their ability to pass through a micropore filter compared to healthy controls.⁹⁵ They may, therefore, be instrumental in disease activations

TABLE 1

Classification of Causes of Hypopyon

Non-infectious	Infectious	Neoplasia/'masquerade'	Corneal
<i>Uveitis</i>	<i>Exogenous</i>	<i>Leukemia</i>	<i>Microbial keratitis</i>
HLA-B27 associated disease	Post-cataract surgery	<i>Lymphoma</i>	Bacterial
Behcet's disease	Other surgery	<i>Retinoblastoma</i>	Fungal
	Trauma	<i>Melanoma</i>	Acanthamoeba
		<i>Metastases</i>	
<i>Iatrogenic causes</i>	<i>Endogenous</i>		<i>Non-infectious</i>
<i>Medical agents</i>	Endogenous endophthalmitis		Chemical injuries
Rifabutin	Toxocara		Mechanical trauma
Traditional eye medicines	Syphilis		Thermal injury
<i>Surgical causes</i>	Hansen Disease		Recurrent erosion syndrome
Lens-associated uveitis	Brucellosis		Immune keratolysis
Retained surgical products	HSV infection		
Laser			

when they show greater adhesiveness, aggregation, and deformation.⁹⁴ Anterior chamber PMNs with late arrival of lymphocytes is also an observed characteristic of Behcet's disease.^{135,190,198}

HLA-B27-associated disease is a common cause of hypopyon. The x-ray crystallographic structure of the HLA-B27 molecule has been described.¹⁰⁹ It may be possible to block the antigen-binding cleft on the molecule and thereby prevent T cell activation. Differences on the humoral arm of the immune system have also been found: raised levels of serum IgA is significantly more common in HLA-B27-positive of uveitis patients ($p < 0.001$) than in patients with idiopathic uveitis.¹²⁸ With further work it will be possible to better understand the pathogenic mechanisms behind these and other uveitic phenotypes.^{132,133,207}

IV. Disorders Causing Hypopyon (Table 1)

A. NONINFECTIOUS DISEASES

Hypopyon results from a minority of conditions causing intense anterior chamber inflammation, the more usual reaction being the formation of aqueous flare and fibrin. The most common conditions in this category are HLA-B27-associated and Behcet's disease-associated uveitis. Recognizing the pattern of ocular disease and the systemic associations that accompany these conditions is important for early diagnosis and appropriate treatment.

1. HLA-B27-Associated Uveitis

The HLA-B27 antigen is a class I major histocompatibility complex molecule whose presence is associated with diseases such as uveitis, psoriasis, Reiter's syndrome, inflammatory bowel diseases (Crohn's disease, ulcerative colitis), seronegative arthropathies (psoriatic arthropathies, ankylosing spondylitis) and Whipple's disease.^{86,106} Uveitis occurs in 5% of patients with ulcerative colitis and Crohn's disease, in 12% of patients with Reiter's syndrome,¹¹⁵ and 25% of patients with ankylosing spondylitis.³³ Of patients with ankylosing spondylitis, 96% are HLA-B27-positive.¹²⁵

HLA-B27-related anterior uveitis is the most common cause of hypopyon uveitis. Anterior uveitis constitutes approximately 80%. Although there is geographical variation in the prevalence of uveitis, a British study found that 52% of patients with acute anterior uveitis (AAU) were HLA-B27-positive.³³ A study in southern California found hypopyon in 11 (7.1%) of 155 patients presenting with AAU.⁵⁰ Nine out of the 11 (82%) were HLA-B27-positive, 1 with Reiter's syndrome, 1 with ankylosing spondylitis, and 6 with no associated systemic disease. Of the 2 HLA-B27-negative patients with hypopyon, 1 had mixed connective-tissue vascular disease and 1 had idiopathic anterior uveitis. Of the 40% of patients who

were HLA-B27-positive, hypopyon occurred in 14.5%, but in only 2.2% of HLA-B27-negative patients. Therefore, most patients with anterior uveitis associated with hypopyon will test positive for HLA-B27. Taking the study period into account, the incidence of hypopyon in AAU is 4.6% and the prevalence is 7.1%, with a prevalence of 8.6% in HLA-B27-positive AAU compared to 2.2% in HLA-B27-negative AAU.¹⁵³ Given that 80% of all uveitis is AAU,⁵¹ HLA-B27 hypopyon uveitis occurs in 5.7% of all patients with uveitis. These figures vary, as HLA-B27 is more common in whites⁵⁰ and less common in the developing world.¹⁷⁵

In order to investigate the differences between AAU that is or is not associated with systemic disease, we looked at aqueous humor samples from the two groups.³⁹ Those patients without associated systemic disease had raised levels of activated CD4+ T cells and reduced B cells, and patients in both groups had reduced levels of the immunoregulatory molecule IL-10 compared to controls.

The clinical approach to patients with hypopyon associated with HLA-B27-associated disease are discussed in Section V (Clinical Approach to Hypopyon). Treatment of HLA-B27-associated anterior uveitis should consist of hourly topical steroid drops and mydriatics. In some patients, hypopyon may develop even after hourly steroids. Periocular steroid injections are effective in these cases. The prognosis for visual acuity is good, particularly for adult patients.⁵⁰

The diagnosis of AAU may bring to light systemic disease associated with HLA-B27 (Table 2). In one study of 236 consecutive patients with AAU, 13% were found to be suffering from a seronegative arthropathy (7% Reiter's syndrome; 6% ankylosing spondylitis).¹⁷⁸ Two-thirds of these patients were unaware of their condition. This is important because early physiotherapy in ankylosing spondylitis can help to maintain mobility and prevent or delay deformity.³⁸ Treatment of the urethritis in Reiter's syndrome is important but does not affect the course of the eye disease.¹⁰⁵

2. Behcet's Disease

Behcet's disease is an aggressive multisystem, inflammatory disorder of unknown etiology, which was originally described as a triad of uveitis with oral and genital ulceration.²⁸ Ocular involvement is characterized by explosive attacks of anterior uveitis with a tendency to cause hypopyon.¹³² Hypopyon iridocyclitis was a major diagnostic criteria for the diagnosis of Behcet's disease in the classification issued by the Behcet Disease Research Committee of Japan in 1987,^{137,191} but it is not a specified criterion in the International Study Group classification of 1990.¹

In about 6% of cases, hypopyon is a presenting feature of Behcet's disease.³⁰ However, the clinical course of Behcet's disease varies geographically, being most aggressive in Japan and the Middle East.¹¹⁵ It has also been suggested that hypopyon in Behcet's disease is less common with the advent of steroids and may, therefore, also vary according to the treatment used.¹⁶⁷ Intriguingly, hypopyon in Behcet's disease is more common in females, despite the fact that ocular involvement tends to be both less common and less sight-threatening in women.¹³⁵ In a Japanese series, macroscopic hypopyon occurred in 12%, with angle-hypopyon visible in 19%¹³⁵ compared to 10–35% in other parts of the world.^{25,30,230} Iridocyclitis without hypopyon occurs in two-thirds of cases.¹³⁵

The main pathological process in Behcet's disease is a small-medium vessel vasculitis that in the anterior chamber leads to the acute suppurative deposition of PMNs and necrotic debris in the anterior chamber. Abundant numbers of PMNs are found in the anterior chamber of eyes with Behcet's uveitis, whether or not they have hypopyon. This is in keeping with the tendency for hypopyon formation.^{190,198} Patients with HLA-B51 are known to have a susceptibility to Behcet's disease. Although this may be of value in establishing a diagnosis, it is less clear how this explains how altered immune response could lead to either Behcet's disease itself or hypopyon formation.¹⁵¹

Clinically, the iritis in Behcet's disease is nongranulomatous and cells circulate freely with the hypopyon characteristically shifting according to gravity and

posture.¹³⁵ Further clinical findings and differential diagnoses are described in Section V and Table 2.

The therapy of uveitis associated with Behcet's disease frequently requires a multidisciplinary approach, involving specialists managing the various systemic manifestations of this highly aggressive condition. Rapid resolution of the hypopyon typically occurs on topical corticosteroid treatment within days without sequelae.¹³⁹ However, posterior segment disease may warrant treatment with systemic prednisolone and other immunosuppressive or cytotoxic agents.^{3,8,112,126,139,147,148,159,228} The use of intravenous methylprednisolone appears to offer a treatment option with a rapid response if the threat to vision is imminent.¹⁷¹ Treatment courses may need to span a number of years.^{30,122} Behcet's disease has a poor prognosis for retention of useful vision,¹²² but hypopyon and anterior uveitis in themselves are not associated with poor outcome.¹⁴⁷ Although the disappearance of hypopyon is an encouraging sign during treatment,²²⁸ the survival of functioning retina, particularly the macula, is the most important factor affecting final visual function.³¹

B. IATROGENIC CAUSES

1. Medical Agents

a. Rifabutin

Rifabutin is an antimicrobial agent used in the prophylaxis and treatment of *Mycobacterium avium* complex, which occurs particularly in patients with AIDS.^{137,154,177} In a report of anterior uveitis in 1990,

TABLE 2

Hypopyon in Systemic Disease

Disorder	Features
HLA-B27 disease	Sacro-iliitis, peripheral arthritis, aphthous stomatitis, psoriatic nail and skin changes, gastrointestinal disturbance, urethritis, aortic insufficiency
Behcet's disease	Race (especially Japanese, Eastern Mediterranean), recurrent aphthous or genital ulcers, skin lesions (e.g., erythema nodosum, acneiform lesions, pseudofolliculitis), arthritis, epididymitis, vascular disease, CNS symptoms
Endogenous endophthalmitis	Immunocompromised states (organ transplantation, leukemia, neutropenia, metastatic neoplasia, pharmacological, nutritional/alcoholic states), intravenous drug abuse, ⁵⁸ diabetes mellitus, ²²⁴ cardiac valve disease, ¹⁷⁶ hepatobiliary infection, ²²⁴ gastrointestinal malignancy, ^{80,66} invasive procedures (hemodialysis, endoscopy, catheterization)
Medical agents	Rifabutin (M. avium prophylaxis in HIV)
Toxocara	Exposure to puppies or lactating bitches, pica, clinical appearance
Syphilis	Evidence of secondary syphilis (macular–papular rash, condylomata accumulata, alopecia, mucosal ulcers, malaise, fever, lymphadenopathy), evidence of tertiary syphilis (gummas, cardiovascular disease, neurosyphilis), co-existent HIV disease
Hansen disease	Erythema nodosum leprosum (painful erythematous skin nodules or plaques, fever, malaise, arthritis, orchitis, lymphadenopathy, proteinuria)
Brucellosis	Previous flu-like illness
Leukemia/lymphoma	Age (young, old), frequent and severe infective episodes, non-acute onset, lymphadenopathy, full blood count with white cell differential, anterior chamber tap and flow cytometry, diagnostic vitrectomy

Mycobacterium avium intracellulare was cultured from the aqueous humor of an HIV-positive patient and the hypopyon attributed to intraocular infection.¹²⁴ Since then, it has become clear that anterior uveitis occurs as a dose-dependent effect of rifabutin at dosages over 300 mg.^{9,86,173} More recently, rifabutin-induced uveitis has been noted in an immunosuppressed pediatric patient without AIDS who underwent lung transplantation.⁹⁹ Rifabutin appears to induce its own metabolism,¹⁸⁸ but this is also increased when clarithromycin and/or fluconazole are added.^{63,89} These adjunctive agents inhibit the metabolism of rifabutin via the cytochrome P-450 system. The effect could also occur with the numerous other agents that also affect this pathway.²⁸ The clinical syndrome varies in severity from mild to severe hypopyon uveitis, occasionally bilaterally. The condition may be asymmetrical with hypopyon in one eye and anterior uveitis in the other.⁸⁹ Sometimes the hypopyon resolves on cessation of rifabutin, recurring when it is restarted.^{21,86,222} With intensive topical steroids the condition resolves within 24 to 48 hours.^{89,111}

Other medications such as cidofovir, pamidronate, and sulphonamides are known to cause anterior uveitis but would not be expected to cause hypopyon.^{47,113,200}

b. Traditional Eye Medicines

In the developing world the use of traditional eye medicines (TEMs)—for example, plant juices or milk mixed with black powder and pounded roots instilled into the conjunctival sac within the last 7 days—represent a major risk factor for the development of hypopyon keratitis.²²⁹ Hypopyon occurred in 19.3% of corneal ulcers with a recent history of TEM use compared to 2.6% in patients who did not use TEMs ($p = 0.004$).

2. Surgical Causes

Intense inflammation occurring immediately postoperatively presents a difficult clinical scenario. Although it is a priority to exclude or treat infection, not all postoperative inflammation is infective, as it may occur in reaction to surgical manipulation or retained physiological or surgical material. Surgical manipulation by itself tends to produce a fibrinous anterior chamber reaction rather than hypopyon. Careful examination for vitritis aids diagnosis: the presence of postoperative hypopyon and clear vitreous on ultrasound examination may suggest either coagulase negative staphylococcal infection or culture negative endophthalmitis.⁴⁸

a. Lens-Associated Uveitis

Lens associated uveitis (LAU) describes a group of conditions that occur when lens proteins are released from encapsulation. Proposed pathogenic

mechanisms include toxicity, autoimmunity to lens proteins, and immunological adjuvant action of bacteria. Phacoanaphylaxis, from residual postoperative soft lens matter, is a proven histological entity,¹⁵ but one of a number of pathological variants. Clinically, there are three forms of LAU. Hypopyon is a typical feature of acute postoperative LAU, differentiating it from raised intraocular pressure, which may also present with pain, reduced vision, and hyperemia. Hypopyon is less common in the second, more indolent, granulomatous form of LAU. There is controversy as to whether this can be differentiated from infective postoperative endophthalmitis associated with *Propionibacterium acnes*, *Staph. epidermidis*, fungi, or other low virulence organisms. A white capsular plaque or a history of recent Nd-YAG capsulotomy would point toward chronic infection. Thirdly, a bilateral, indolent form of LAU bears similarities to sympathetic ophthalmia. Bilateral LAU tends to occur following surgery or trauma to the fellow eye long after surgery in the first and is usually sequential rather than simultaneous as in sympathetic ophthalmitis.¹²³

Phacolytic glaucoma prior to cataract extraction may cause intense inflammation with hypopyon. In one retrospective series, 3 of 135 eyes had hypopyon.²⁰⁷ Definitive treatment of LAU is complete removal of lens remnants from the eye. Pre-operative and post-operative inflammation should be treated with topical steroids.

Sterile postoperative hypopyon tends to resolve with topical steroid treatment,⁷⁵ although subconjunctival, intracameral, and oral administration may be appropriate. Ocular morbidity occurs if intraocular inflammation or raised intraocular pressure is allowed to persist untreated. It may be appropriate to consider washing out exogenous, retained toxins.

b. Retained Surgical Products

A heat-stable endotoxin persisting in ultrasonic equipment cleaning solution appeared to be responsible for a cluster of 21 cases of postoperative hypopyon uveitis occurring over 20 weeks in one location.¹⁷³ Pyrogens in poorly sterilized HPMC containers appear to have been the mechanism involved in clusters of sterile postoperative hypopyon/endophthalmitis that we have treated. Elsewhere, apparent hypopyon in four patients after cataract surgery was found to consist of a sterile fluid collection anterior to Descemet's membrane.¹⁹⁴ The presence of "ghost cells" in the anterior chamber has been confused with hypopyon in a patient following cataract surgery with pre-existing vitreous hemorrhage.¹⁶⁹ Sterile postoperative hypopyon tends to resolve with topical steroid treatment,⁷⁵ although subconjunctival, intracameral, and oral administration may be appropriate. Ocular

morbidity occurs if intraocular inflammation or raised intraocular pressure is allowed to persist untreated. It may be appropriate to consider washing out exogenous, retained toxins.

The uveitis-glaucoma-hyphema (UGH) syndrome was more common in the 1980s when iris clip and rigid anterior chamber intraocular lens implants were used. These were believed to chafe on the iris. The syndrome has been reported with posterior chamber lens implants.⁵⁹

Sterile hypopyon was a complication in 10–28% of patients undergoing macular hole surgery with bovine thrombin-activated tissue sealant.^{153,154,216} The reason for the inflammation may have been a hypersensitivity reaction to the bovine thrombin or to impurities within it.¹⁵⁴ However, thrombin itself is an immunologically active molecule that acts via cell receptors to influence capillary permeability and promotion of inflammation.^{23,134} Patients should be treated aggressively with topical steroids. A response is expected within 48 to 72 hours with resolution by one week.¹⁵⁴ However, the patient should be carefully monitored for deterioration and advancing postoperative endophthalmitis.¹⁵⁴

Finally, two cases from a retrospective review of 30 patients undergoing vitrectomy and silicone oil placement (without thrombin) developed fibrinous postoperative uveitis with hypopyon.¹⁰¹ The authors considered panretinal photocoagulation and impurities in the oil to be possible contributing factors. In such cases the patient must be closely observed for the development of endophthalmitis.

c. Laser

Hypopyon following Nd-YAG laser peripheral iridotomy has been reported.^{42,193} In angle closure glaucoma, hypopyon formation is stimulated by necrotic iris tissue.^{72,187} Such cases should resolve with conventional treatment for angle closure glaucoma.

Argon laser panretinal photocoagulation has been reported to cause hypopyon uveitis.¹⁹² The underlying mechanism is almost certainly anterior segment ischemia. Panretinal photocoagulation triggered hypopyon in another patient, who may have had an ischemic anterior segment following the placement of an encircling band for retinal detachment repair.¹¹³ Care should, therefore, be taken when considering panretinal photocoagulation in a patient with risk factors for anterior segment ischemia. Ischemic mechanisms should be borne in mind if a hypopyon is encountered in such circumstances.

C. INFECTIOUS DISEASES

1. Exogenous Disease

Endophthalmitis is an inflammation involving at least one coat of the eye and its adjacent cavity.²²⁷ It

is characteristically associated with hypopyon, reduced vision, and vitritis. Hypopyon endophthalmitis most commonly occurs after surgical or traumatic breach of the ocular coats, but it can also occur from distant infective sites, such as heart valves (endogenous or metastatic).

Suppuration infection is the classic sequel to infection anywhere in the body whereby pus forms as a result of the breakdown and exudation of inflammatory cells, tissue products, and microorganisms. Infective hypopyon forms if an organism enters the eye via surgical or traumatic penetrating injury or by endogenous blood-borne spread and produces pus in the anterior chamber. Staphylococci, streptococci, and pneumococci are the commonest pyogenic organisms encountered.

a. Hypopyon Following Cataract Surgery

Hypopyon uveitis occurring after cataract surgery should be assumed to be infective until proven otherwise. Exfoliative skin conditions increase the risk and should be vigorously treated preoperatively with lid hygiene and possibly antibiotic to reduce the pathogenic load.¹²⁰

Clinical symptoms vary (Table 3). In a review of 90 cases of coagulase-negative staphylococcal endophthalmitis, 73% presented with hypopyon, yet only 16% complained of ocular pain.^{56,157} Moreover, florid ocular signs, such as marked lid swelling, chemosis, and purulent external ocular infection, were seen in only 11%. In the endophthalmitis vitrectomy study, 85.7% had hypopyon at baseline. Other features that should alert to this diagnosis are wound abnormalities, which are found in 5.2%, and absent red reflex, which is found in 32%.² The presence of a large hypopyon positively predicted poor final vision. In eyes in which a retinal vessel could be visualized, no gram-negative organisms were grown and positive cultures were obtained in only 38% of cases.¹⁰⁰ Moreover, florid ocular signs, such as marked lid swelling, chemosis, and purulent external ocular infection, were seen in only 11%.

The time elapsed since surgery is an important factor in determining whether hypopyon develops. Hypopyon appears to occur more commonly with subacute or chronic infections, as the hypopyon has time to develop before the patient presents with fulminant signs.¹⁵⁶ Whereas staphylococcal disease commonly presents within one week postoperatively, endophthalmitis due to *Propionibacterium*¹⁵⁷ typically occurs after 2–10 months. This may occur following release of bacteria from a capsular abscess after Nd-YAG laser capsulotomy as propionibacteriae may be released from a capsular abscess.^{131,204} Between 44–63% of cases of *Propionibacterium acnes*-endophthalmitis

TABLE 3
Ophthalmic Findings in Hypopyon

Cataract surgery	Endophthalmitis (acute/chronic), lens associated uveitis (residual lens fragments), significant iris trauma, UGH syndrome, impurities in intraocular fluids or viscoelastic
Vitrectomy	Endophthalmitis, impurities in silicone, thrombin
Laser	Nd:YAG iridotomy, panretinal coagulation (e.g., proliferative diabetic retinopathy; CRVO)
Ocular trauma	Mechanical and chemical
Corneal disease	Predisposition to infection: (contact lens use and abuse, ocular surface disease, trauma), HSV, recurrent erosions, traditional eye medicines
Raised intraocular pressure	Mature cataract: (phacolytic glaucoma), Nd: YAG laser iridotomy, angle closure glaucoma (iris ischemia), endophthalmitis from leaking bleb.
Endophthalmitis	Clinical features: reduced visual acuity, lid edema and erythema, conjunctival hyperaemia and chemosis, corneal edema, vitritis, retinal hemorrhages and periphlebitis. Consider: AC and vitreous tap, retained lens products, degree of surgical trauma, recent reports of postoperative endophthalmitis associated with surgical products, masquerade
Uveitis	Anterior uveitis: HLA-B27 disease, herpetic iridocyclitis Vitritis: Behcet's, toxocara, syphilis, Hansen disease, brucellosis Consider: endogenous endophthalmitis, masquerade syndromes
Malignancies	Retinoblastoma, melanoma, metastases (pseudohypopyon)

exhibit hypopyon, and this finding often points the way to successful diagnosis and treatment.^{131,232}

When infective endophthalmitis is suspected, management must include aqueous and vitreous sampling with administration of intracameral antibiotics, such as amikacin and ceftazadine/vancomycin.¹⁵² The Endophthalmitis Vitrectomy Study found no benefit in giving systemic antibiotics.⁵⁷ Low-grade infections with propionibacteriae may settle with topical corticosteroids and intravitreal vancomycin.²³² However, when bacteria are thought to be retained in capsular remnants, it is appropriate to remove the entire capsule and implant with secondary placement of an anterior chamber intraocular lens at a later date, if required.

Histoplasma capsulatum endophthalmitis must be considered in patients who have visited endemic areas, such as the Ohio and Mississippi valleys of the USA. *Histoplasma capsulatum* has been cultured and identified from a vitreous sample in a patient from an endemic area presenting with hypopyon endophthalmitis and a vitreous wick syndrome 2 months after cataract surgery.¹⁷⁰ The infection did not respond to repeat vitrectomies, intracameral and intravenous amphotericin, and the eye was enucleated. *Histoplasma* probably entered via the wound, as *Histoplasma* organisms were identified in the vitreous wick and on the iris and ciliary body; however, there was no history of systemic upset, and blood serology was negative for *Histoplasma*, so this may have represented exogenous infection.

b. Hypopyon Following Other Surgery

Glaucoma filtration surgery predisposes to intraocular infection. Common organisms include streptococci, haemophilus, and staphylococci, organ-

isms that typically gain access to the eye via the filtering bleb, particularly if it is thin-walled or leaking.¹³⁸ In one study of 14 patients with trabeculectomy bleb infections, six eyes had hypopyon.³⁵ Revision of aqueous tube shunts is associated with hypopyon.⁶⁵ In another series, removal of a 4/0 chromic suture securing a Molteno tube was associated with hypopyon in 7 of 27 eyes. Although no organisms were cultured, hypopyon resolved with routine antibiotic therapy in 6 of these eyes.²⁰

The presence or absence of vitritis is often used to distinguish blebitis from bleb-associated endophthalmitis, although the former may be the prodrome of the latter.⁴¹ In the presence of a whitened bleb and hypopyon uveitis, infection should be assumed. An anterior chamber tap should be considered for blebitis that may be considered as a limited form of endophthalmitis, the bleb fluid being in communication with aqueous. Anterior and vitreous chamber sampling is mandatory for endophthalmitis. Blebitis can be treated with broad-spectrum intensive topical and systemic antibiotics, such as G-Ofloxacin and G-Cefuroxime with oral ciprofloxacin 750 mg BD for 5–7 days. Close observation must be maintained, as blebitis can become bleb-related endophthalmitis over a period as short as 8 hours. If it is not possible to examine the patient at such intervals, vitreous sampling and intracameral treatment (e.g., with vancomycin 1 mg and ceftazidime 2 mg) should be considered.

Other less usual sources of hypopyon endophthalmitis include scleral perforation during strabismus surgery²¹⁴ and after repeated transplantation of human amniotic membrane onto the corneal surface.⁷³ Hypopyon keratitis has also occurred following uncomplicated muscle surgery.²⁷

Following penetrating keratoplasty, a patient developed hypopyon uveitis, recurrent conjunctivitis, an epithelial corneal defect and an endothelial plaque.²¹⁸ The graft failed and the patient was regrafted, enabling histological identification of cytomegalovirus (CMV) keratitis. This diagnosis should be borne in mind in similar circumstances. An atopic patient cared for by the authors developed endophthalmitis secondary to *Candida keratitis* after corneal graft surgery. The vigorous hypopyon uveitis that developed 12 hours following intracameral injection of amphotericin was believed to be a Jarisch-Herxheimer reaction to degenerate fungal proteins.

Infection has been estimated to occur in 0.25–0.70% of eyes after radial keratotomy, although only about 10% of these breach the ocular coats.⁹⁷ Entry of organisms into the anterior chamber has been reported without a history of full-thickness perforation, although microperforations may not be clinically obvious.^{60,87,129} Hypopyon endophthalmitis has been reported after laser in-situ keratomileusis with a pneumococcal keratitis developing 3 days postoperatively.¹⁴³ *Aspergillus flavus* keratitis²⁰² and pneumococcal keratitis⁴⁹ have both recently been reported after LASIK.

c. Trauma

Hypopyon uveitis following recent penetrating ocular trauma should be assumed to be infected until otherwise proven.¹³⁰ The nature of the injury should guide the decision to give antimicrobial prophylaxis, or treatment should be given, as organisms causing post-traumatic endophthalmitis differ from those causing post-operative endophthalmitis with relatively higher proportions of gram-negative bacteria and fungi.^{6,7} Aqueous or vitreous samples should be taken during primary repair.⁷ Intracameral agents form the backbone of therapy, although there may be a greater role for systemic antibiotic therapy in traumatic endophthalmitis where the blood–ocular barrier has been disrupted.

2. Endogenous Infection

a. Endogenous Endophthalmitis

Endogenous endophthalmitis is the infection of intraocular tissues resulting from blood-borne spread of infection. The condition is uncommon, but it may be underdiagnosed because the infective etiology may be missed. It may be classified as focal or diffuse; anterior or posterior; fungal or bacterial. Hypopyon may occur in all forms of endogenous endophthalmitis but particularly with anterior diffuse type.⁸⁰

The majority of patients have either an associated premorbid medical condition or a recent history of an invasive procedure elsewhere in the body¹⁷² (see

Section V and Table 2). The right eye is affected twice as often as the left, possibly because of the more direct passage of the right innominate artery to the right carotid and then the right ophthalmic artery.⁸⁰ Blood-borne organisms are thought to most commonly enter the eye via central retinal artery and ciliary arteries, lodging in capillaries and establishing suppurative foci in the retina.¹¹⁹ From there, infection crosses the blood–ocular barrier, either by sheer concentration or by altered vascular endothelial permeability, in order to establish further foci in the favorable environment of the vitreous, eventually reaching the anterior chamber.²²³ Less commonly, the primary focus may be in the iris or ciliary body where PMNs are recruited to form microabscesses which rupture in to the anterior chamber.

Although pathogens vary from region to region, *Candida* is the single most common pathogen,⁵⁵ causing characteristically posterior focal then diffuse disease. Other fungi include *Cryptococcus neoformans*, *Aspergillus* species, *Histoplasma capsulatum* and *Blastomyces dermatitis*. Gram-negative organisms represent an ever increasing proportion of bacterial endophthalmitis (70% of cases in a recent Asian series).²²⁴ *Bacillus cereus*,⁸⁰ *Klebsiella pneumoniae*,⁴⁰ and *Fusarium* species¹⁶¹ are the most common bacterial pathogens tending to occur with endogenous endophthalmitis, commonly occurring in relation to intravenous drug use and diabetes, pyogenic liver abscesses, and intravenous drug abuse, respectively. *Neisseria meningitidis*, *Listeria monocytogenes*, and *Haemophilus influenzae* may cause overwhelming infection in an otherwise healthy individual.¹¹⁸

Among 14 reported cases of *Listeria endogenous* endophthalmitis, four patients presented with dark hypopyons that tended to darken as the disease progressed.^{13,21,34,61} It is possible that the pathogen caused iris necrosis, leading to the hypopyon's dark hue. Another report describes a pink-colored hypopyon associated with *Serratia marcescens* endophthalmitis that was not found histologically to contain red blood cells.¹⁰

Clinically, any patient with endophthalmitis in the absence of trauma or surgery to that eye should be investigated for an associated systemic condition. Differential diagnosis is discussed in Section V.

Early recognition and treatment of systemic fungal infection is the most important factor in the prevention of endogenous endophthalmitis.¹⁸⁵ Once infection is established, a thorough ocular and systemic examination is required to search for the origin of the infection and to establish an impression of the patient's immunocompetence. Initial investigations should include complete blood count, ESR, serum biochemistry, and cultures of vitreous, aqueous, blood, and urine. Treatment of the ocular infection

involves intracameral and systemic antibiotics or antifungals. Endogenous endophthalmitis may be more amenable than exogenous endophthalmitis to systemic therapy because the highest concentration of organisms are on the blood side of the blood–ocular barrier.⁸⁰ Vitrectomy may or may not be appropriate when considering the patient's general health.

b. *Toxocariasis*

Toxocara canis is a nematode that can cause a number of patterns of ocular disease. Hypopyon occurs with the endophthalmitic form of ocular toxocariasis, in which the host response is unusually vigorous.²³⁵ A layered hypopyon may form despite a relatively quiet anterior chamber. This contrasts with other uveitides, demonstrating that hypopyon is not simply a generic response to intense anterior segment inflammation. Cytologically, the condition is characterized by eosinophils surrounded by epithelioid cells, giant cells, lymphocytes, plasma cells, and fibroblasts. The diagnosis is essentially clinical.¹¹⁵ A history of pica or contact with puppies of less 3 months old should be sought.¹⁸⁴ Serological investigations may not be helpful, as histologically confirmed ocular disease has not been associated with absence of anti-toxocara antibodies.¹⁶⁰ Whereas immunofluorescent antibody techniques are specific but insensitive,⁷⁷ ELISA titres of > 1:8 have specificity and sensitivity greater than 90%.¹⁶⁸ A weakly positive result may represent background infection, particularly in endemic areas. Other causes for hypopyon uveitis with leukocoria, such as retinoblastoma,⁶² should be sought with clinical examination, ultrasound, or computerized tomography of the posterior segment.^{189,206} Hypopyon anterior uveitis usually responds to topical steroids, but concurrent posterior segment inflammation usually requires systemic steroids.¹¹⁵ Antihelminthic drugs or laser photocoagulation may increase the inflammatory reaction, and their use is controversial.^{149,184,188}

c. *Syphilis*

Hypopyon uveitis occurs following systemic infection with *Treponema pallidum*. The condition can mimic many other ocular conditions²⁰⁵ and should always be considered in the differential diagnosis of hypopyon, because both secondary and tertiary syphilis may present as anterior uveitis with hypopyon.²²¹ In one study, 8% of patients with secondary syphilis had uveitis (n = 89).⁸⁹ Before penicillin was demonstrated to be a useful treatment for syphilis in 1943, between 6% and 82% of uveitis was attributed to syphilis. The widespread availability of antibiotic therapy and more rigorous diagnostic criteria reduced this figure to under 1%.⁸⁸ However, in the era of HIV/AIDS, this figure rose again with some cases

of AIDS presenting with intraocular luetic inflammation.^{71,111} A recent review of 535 patients found positive luetic serology (FTA-Abs) in 8% of 552 patients attending a uveitis clinic. Syphilis was thought to be the sole cause of uveitis in 4.3%.²⁴

It is, therefore, still prudent to perform syphilitic serology when investigating patients with uveitis, particularly if they are not adequately responding to corticosteroid therapy. There are two categories of serological tests: treponemal antibody and nonspecific (reagin) antibody tests. A negative treponemal test, such as the indirect fluorescent treponemal antibody adsorbed (FTA-ABS) test, effectively excludes ophthalmic and neuro-ophthalmic syphilis, except in 20% of those treated during primary syphilis.²¹⁰ Nonspecific antibody tests such as rapid plasma reagin (RPR) or Venereal Disease Research Laboratory (VDRL) give a measure of disease activity but become negative over time. Care should be taken, as results may be falsely positive in patients with Lyme disease, which can also cause ocular inflammation.²³⁴ Lumbar puncture is recommended when there is posterior uveitis, particularly with signs of neurosyphilis (light-near dissociation, optic neuropathy, cranial nerve palsies) or a history of previously treated syphilis (e.g., in HIV).²²¹ Treatment is with high dose systemic penicillin or a third generation cephalosporin for 3 weeks.²⁰⁵ Oral corticosteroids should be considered to prevent a Jarisch-Herxheimer reaction.²⁰⁹

d. *Hansen Disease*

Hansen disease (leprosy) is caused by systemic infection with *Mycobacteriaceae leprae*. It is a major public health problem in populated parts of the developing world with 1 million new cases estimated each year by the World Health Organization. The prevalence of most ocular manifestations of leprosy increases with the duration of untreated systemic infection.²¹¹ One study found 6% of patients had uveitis at an average of 10 years after onset of disease, rising to 20% by 24 years.²¹¹ An increase in the CD4:CD8 (T helper:T suppressor) ratio may cause a release of bacillary antigens from macrophages.¹⁵⁸ These combine with antibodies, which fix complement leading to PMN recruitment, thereby leading to hypopyon formation. Major histocompatibility DR alleles have been implicated in conferring susceptibility of leprosy patients for uveitis.¹⁰² Uveitic patients have a tendency to be HLA-DR2–positive and HLA-DR4–negative.¹⁰² Ocular infection and anterior uveitis in particular are common because of cooler temperatures, abundant neurovascular tissue, and safe harbor from the immune system.⁹³

Uveitis is the major cause of visual loss in leprosy, whether directly or indirectly through cataract for-

mation.⁴ An African study found 74 of 311 patients (24%) to have impaired vision due to cataract (21%), neurotrophic keratopathy (14%), or uveitis (10%).⁴ The uveitis is most commonly chronic with insidious effects.⁶⁴ Acute hypopyon iridocyclitis occurs particularly in the erythema nodosum leprosum (type II) immune-complex reaction, occurring with disseminated infection and little cell-mediated immunity (lepromatous leprosy).^{68,69} Leprosy-associated anterior uveitis should be treated with topical steroids, whereas the systemic condition requires systemic treatment according to the WHO protocol with Rifampicin, Lemprene, and Dapsone.⁵³

e. *Brucellosis*

Brucellosis is a systemic bacterial infection with an incidence of 0.1/100,000 in the USA.¹¹ It is transmitted by either direct contact or airborne spread from sheep, cattle, swine, and dogs to humans who are commonly farmers or abattoir workers. Hypopyon may occur with an anterior uveitis or more rarely, endophthalmitis.⁹ The disease should be managed in consultation with a specialist in infective diseases, as severe systemic disturbance may follow an initial flu-like illness. The hypopyon anterior uveitis responds rapidly to topical steroids, but systemic disease requires antibiotic therapy.⁴³

f. *Herpes Simplex Virus Infection*

Severe herpetic iridocyclitis has been reported to be accompanied by hypopyon.⁵² However, this is so rare that other causes for hypopyon should be sought.

D. NEOPLASIA/MASQUERADE CONDITIONS

It is important to consider the possibility of malignancy masquerading as hypopyon uveitis, particularly in the young and the elderly.²³³ Hypopyon may be simulated by tumors, such as leukemia, lymphoma,⁸¹ and retinoblastoma.^{22,180} Although they may develop due to secondary inflammatory activity, they may arise as a result of direct discharge of leukemic or necrotic cells into the anterior chamber. Because such collections do not consist of pus, they may be referred to as pseudohypopyons.

1. Leukemia

Leukemia can involve all parts of the eye by direct infiltration, hemorrhage, or ischemia.¹⁷ Only 1 in 6 patients has symptomatic ocular involvement before death.¹¹⁴ Hypopyon may develop in acute lymphoblastic leukemia (ALL),^{36,54,98,197} acute myeloid leukemia (AML),^{17,63,127} and chronic myeloid leukemia (CML).^{117,181} Ocular involvement is usually a secondary finding in a patient with known leukemic disease, but the clinician must be vigilant, as anterior

uveitis, with or without hypopyon, can also be a presenting feature of the disease *de novo*^{19,32} or an initial feature of a relapse.^{5,36,37,46,47,81,91,98,104,116,183,196,231}

Anterior chamber involvement, particularly as an isolated finding, is much more common in ALL^{36,54,83,98,197,231} than AML, in which the patient tends to be systemically unwell.^{63,177} In ALL, anterior segment involvement has been estimated at between 2.5 and 18% of relapsed cases, depending on the "stage" of the disease.^{19,81,146,174} Whereas ocular involvement was found in 8% (52) of 657 children with ALL,¹⁷⁴ a 2-year prospective study of 53 patients failed to find at initial presentation in any children with AML.¹⁰³ However, there have been reports of hypopyon uveitis as an isolated sign of relapse of AML¹¹ and two reports of leukemic pseudohypopyon in CML, which may have been associated with blast crisis.^{117,181}

Clinical findings in leukemic uveitis are described in Section V and Table 2. A blood-streaked hypopyon that fails to resolve with local or systemic corticosteroid therapy should raise suspicion and prompt an anterior chamber (+/- vitreous) tap to be sent for both cytology and culture. Ocular involvement is generally associated with evidence of malignant cells at other sites and a thorough search should be undertaken, although the eye may be the sole site of renewed disease.^{17,46,54,82,98,179,197}

All ophthalmic manifestations of leukemia, including hypopyon uveitis, confer a poor prognosis for survival because of their correlation with bone marrow relapse or spread to the central nervous system.¹⁵⁰ However, the immune privilege and blood ocular barrier of the eye confers sanctuary on tumor cells lodged therein so that systemic chemotherapy is ineffective.^{54,98,124} Therefore, residual ophthalmic lesions do not necessarily mean that the disease has not been eradicated from the rest of the body.^{98,181} The most effective treatment for ocular infiltration is irradiation, the extent of which should be considered in the light of possible systemic disease and ocular side effects.^{84,85}

2. Lymphoma

Non-Hodgkin's lymphoma, either systemic or ocular, may masquerade as hypopyon uveitis (Fig. 1).^{44,78,219} This may be the initial presentation of systemic disease^{78,219} or a manifestation of known progressive disease, which will be evident from careful history taking. In contrast to hypopyon uveitis, pseudohypopyon in patients with ocular lymphoma may develop over months despite steroid treatment,⁷⁸ although a partial response may also occur. Therefore, clinical suspicion should be raised in an elderly person responding inadequately to steroid treatment, and a full systemic history and examination should be undertaken. Appropriate investigations include a

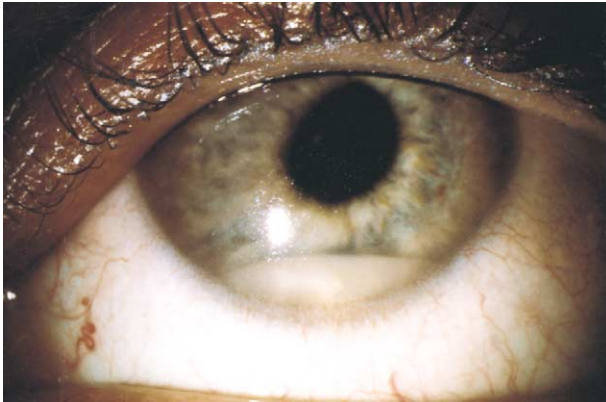

Fig. 1. Pseudohypopyon due to intraocular lymphoma.

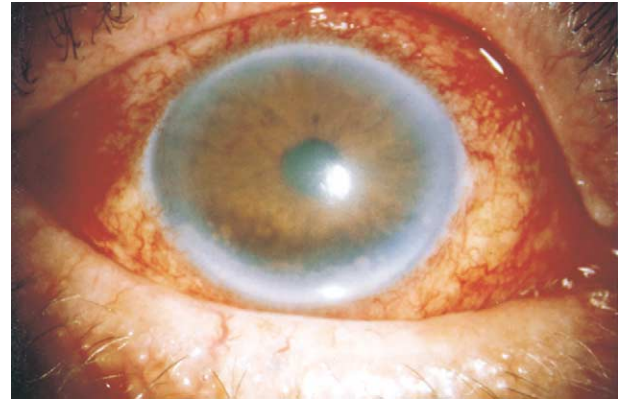


Fig. 2. Black pseudohypopyon with secondary iris deposits due to intraocular melanoma.

full blood count with differential and, when feasible, flow cytometry of anterior chamber aspirate.⁷⁸ A diagnostic vitrectomy appears to be helpful in up to one-third of cases of chronic uveitis.²¹⁵ Trudeau et al, reviewing 87 cases in the literature, found 83% to have systemic or central nervous system involvement and, therefore, recommended radiation therapy to the whole brain and eyes, followed by systemic chemotherapy.²¹²

3. Retinoblastoma

Retinoblastomas have a tendency to form pseudohypopyon, because they are friable tumors with poor cell-to-cell attachment because of defective or absent zonulae adherens.^{71,76,171} In one series, retinoblastoma presented as pseudohypopyon in 2% of 185 cases.²² Pseudohypopyon may form either from seeding of retinoblastoma cells that may seed via the vitreous or by shedding of necrotic tumor cells. The difficulty in distinguishing between uveitis and retinoblastoma-induced inflammation may cause diagnostic delay and allow time for metastasis. This can be avoided by cytological analysis of cells obtained by aqueous paracentesis.

4. Other Tumors

Significant intraocular inflammation is uncommon in melanoma. Extensive anterior and posterior inflammation is more consistent with inflammatory disease than with choroidal melanoma.¹⁴² However, when hypopyon does occur, it may aggregate into clumps (Fig. 2). There has been a report of black pseudohypopyon occurring with both primary choroidal and metastatic cutaneous melanoma.^{12,225}

Whereas metastatic tumors of the eye are the most common form of intraocular malignancy,⁶⁷ they, too, rarely cause pseudohypopyon, although this may occur if lesions are neglected and grow to a large size. In such cases, the diagnosis may be made by aqueous paracentesis.¹⁸⁶

E. CORNEAL DISORDERS

Numerous corneal insults, including both chemical and infective assault, are capable of causing a sterile hypopyon. The hypopyon, which forms with microbial keratitis (Fig. 3), may consist of infective material particularly with fungal keratitis, although it is usually sterile.²²² The pathogenic mechanisms involved are different for alkali injuries and microbial keratitis, but both involve the release of potent chemotactic factors.

1. Microbial Keratitis

Hypopyon has been reported after corneal infections with diverse pathogens, such as *Staphylococcus aureus*,¹⁰⁸ *Moraxella*,⁷⁴ *Nocardia*,²⁰³ non-Tuberculous mycobacterial keratitis,^{92,145} *Acanthamoeba*,^{18,226} fungi,^{29,195} *Cytomegalovirus*, and *Herpes simplex* viral keratitis with polymicrobial superinfection.^{107,213,218} Fungal keratitis^{14,90,203} is the most likely external ocular infection to cause infective hypopyon because of its rapid corneal penetration. The hypopyon resulting from bacterial keratitis is more likely to be sterile, resulting from the exudation of proteins and inflammatory cells via increased iris vascular permeability.

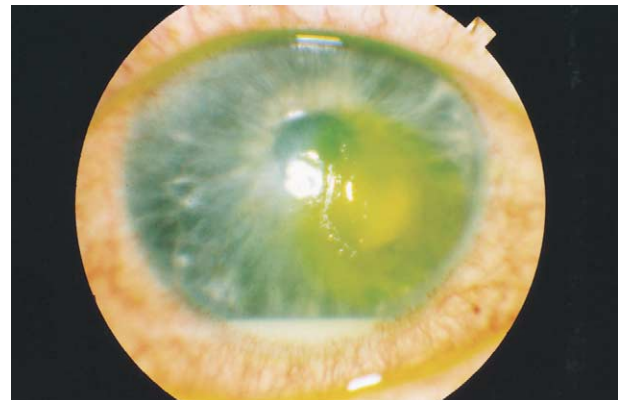


Fig. 3. Hypopyon due to microbial keratitis.

Bacteria may also penetrate the corneal stroma, but tend not to gain access to the anterior chamber²¹⁷; the most destructive are *Neisseria* and *Pseudomonas* species.¹⁵⁵ In the presence of infection, bacterial proteins direct the migration of PMNs toward the anterior segment via chemotaxins, such as interleukin 8, which is released from the corneal epithelium and stroma.¹³⁶ This eventually leads to hypopyon with PMNs predominating, but monocytes, macrophages, giant cells, and erythrocytes also being present.^{70,140,141,208} Accumulated inflammatory cells can sometimes affect permeability of the local corneal endothelium resulting in edema and passage of cells.²²²

Clinically, the hypopyon associated with microbial keratitis is typically heaped up centrally rather than at its edges. Hypopyon due to infective and noninfective corneal disease are identical in appearance. Therefore, corneal scrapes should be obtained; the chance of obtaining a positive culture result increases in the presence of hypopyon.¹⁶ With modern broad-spectrum antibiotics, most infective corneal ulcers resolve with a variable degree of scarring. The presence of hypopyon in microbial keratitis is a poor prognostic sign, increasing the risk of visually disabling corneal opacity.¹³³ However, it is less important than the nature of the preceding pathology, the extent of ulceration at presentation and the organism involved.⁴⁵

Following penetrating keratoplasty, a patient developed hypopyon uveitis, recurrent conjunctivitis, an epithelial corneal defect, and an endothelial plaque.²¹⁸ The graft failed, and the patient was re-grafted, enabling histological identification of cytomegalovirus (CMV) keratitis. This diagnosis should be borne in mind in similar circumstances.

Infection has been estimated to occur in 0.25–0.70% of eyes after radial keratotomy, although only about 10% of these breach the ocular coats.⁹⁷ Entry of organisms into the anterior chamber has been reported without a history of full thickness perforation due to microperforations, which may not be clinically obvious.^{60,87,129} Hypopyon endophthalmitis has been reported after laser in situ keratomileusis with a pneumococcal keratitis developing 3 days postoperatively.¹⁴³ Although it is possible that corneal surgery alone can be responsible, infection should be sought.

2. Noninfectious Corneal Injuries

Hypopyon uveitis is common following trauma, particularly alkali injuries. Collagen breakdown product(s) from alkali injury might be the initial signal for PMN invasion of the cornea and the subsequent activation of the respiratory burst.¹⁶³ When damaged by alkali, all layers of the cornea rapidly generate low molecular weight, highly diffusible, chemoattractant peptides (N-acetyl-Pro-Gly-Pro and

N-methyl-Pro-Gly-Pro) for PMNs.^{162,164,166} Citrate and metalloprotease inhibitors inhibit this locomotory stimulus.^{163,165} Mechanical trauma, thermal burns and immune inflammatory reaction (e.g., rheumatoid keratolysis) are additional stimuli capable of producing hypopyon.

Hypopyon occurs in association with recurrent erosion syndrome. In a review of 11 patients with a history of recurrent erosion syndrome who developed corneal infiltrates, hypopyon was found in three despite an unusually low positive culture rate.⁹⁶ Injury to the corneal epithelium alone can produce a PMN chemotactic factor.⁷⁹

The history should distinguish between these etiologies. The ocular environment should be made conducive to epithelial healing (e.g., artificial tears, mucolytics, punctal occlusion, correction lid position). Topical broad spectrum antibiotics (e.g., ofloxacin) should be used, particularly where infection is suspected. Inflammation should be reduced, but care should be taken to reduce or stop topical corticosteroids during the second week after alkali injuries and rheumatoid keratolysis, as such treatment is associated with increased risk of corneal perforation.

V. Clinical Approach to Hypopyon

The various clinical entities in which hypopyon may form (Table 1) must be dealt with first in relation to the patients' medical (Table 2) and ophthalmic (Table 3) status.

A. ASSOCIATED SYSTEMIC CONDITIONS

Hypopyon uveitis is most commonly encountered in association with HLA-B27 AAU. A careful history will often determine the presence of associated systemic conditions (Table 2). For example, the back pain of HLA-B27-associated AAU is present in 60–84%.^{26,178} This is insidious, chronic, worse in the morning, improving with exercise, and non-dermatomal, in contrast to mechanical back pain, which tends to be sudden in onset, worse with exercise, self limiting, and dermatomal. Peripheral joint disease tends to be pauciarticular, asymmetric, and peripheral, often causing swelling of an entire digit (dactylitis). In these patients, the uveitis is characteristically anterior, acute, unilateral, of less than 3 months' duration, recurrent, and nongranulomatous with fibrin. There may be raised intraocular pressure, posterior synechiae, and cystoid macular edema. Males are three times as likely to be affected as females, and whites are more commonly affected than blacks¹²¹ or Japanese.¹⁸²

In contrast, hypopyon in association with Behcet's disease is more common in patients from Japan and the Eastern Mediterranean.¹¹⁵ Uveitis in Behcet's disease is also more likely to be of longer duration, bi-

lateral, involve the posterior segment, and have a poorer visual prognosis. The hypopyon may be mobile, forming and disappearing rapidly.¹³⁵ The arthropathy in Behcet's disease can be similar to HLA-B27 disease, but 98% of patients would be expected to have a history of oral and genital ulceration.¹⁴⁴ Other systemic findings are listed in Table 2.

In the absence of a prior history of trauma or surgery, hypopyon with signs of endophthalmitis (see Table 3) should prompt careful medical history, examination, and investigations to seek conditions associated with endogenous endophthalmitis (Table 2). The occurrence of hypopyon uveitis in such patients may represent reactivation of underlying leukemia.¹⁶¹ Dark hypopyons or those streaked by blood may be associated with *Listeria* or *Serratia*.^{10,13,61}

Differential diagnoses of endogenous endophthalmitis in immunocompromised patients include pseudohypopyon, as well as rifabutin-associated hypopyon and syphilis uveitis in HIV patients (Table 2).

The eye in pseudohypopyon is relatively quiet with little pain, visual loss, hyperemia, or lid swelling, and without posterior synechiae, in contrast to endogenous endophthalmitis.^{17,231} The diagnosis should be considered particularly in children and in elderly patients who fail to respond to local therapies. The pseudohypopyon may be blood-streaked or dark (melanoma).¹² The major differential diagnoses of hypopyon with leukocoria in an infant are retinoblastoma and toxocara uveitis (Table 2). The diagnosis may be confirmed by systemic history and examination, full blood count and differential, and definitively by anterior chamber tap.

The travel history and racial background of a patient with hypopyon may give clues to the diagnoses of Hansen's disease, toxocara, Behcet's Disease, and the use of traditional eye medicines. Contact with animals should alert the clinician to the possibilities of toxocara and brucellosis.

B. PAST OPHTHALMIC HISTORY

Endophthalmitis is the first diagnostic consideration in hypopyon following recent penetrating trauma or surgery such as complicated cataract surgery or glaucoma surgery. In full-blown cases, the clinical picture is clearer, but it is still essential to attempt to confirm microbiological organisms by anterior chamber and vitreous tap (Table 3). In less clear-cut cases, other noninfectious causes should be considered (Table 3). Where hypopyon clears with corticosteroid therapy and residual chronic inflammation remains, the decision to treat conservatively is guided by the absence of visual deterioration, discomfort, cystoid macular edema, and the absence of a posterior capsular plaque.

Following vitrectomy surgery, sterile hypopyon may occur in association with the use of thrombin,

panretinal photocoagulation, or silicone oil containing impurities. However, the exclusion of infectious endophthalmitis is of primary importance (Table 3).

The differential diagnosis of hypopyon in the context of raised intraocular pressure includes phacolytic glaucoma, response to laser iridotomy or angle closure glaucoma, and, finally, endophthalmitis from a leaking filter bleb (Table 3).

Most patients with hypopyon and isolated hypopyon anterior uveitis will have HLA-B27 disease, but, rarely herpetic disease may be responsible. Posterior uveitis must be differentiated from endogenous endophthalmitis and masquerade syndromes by careful systemic history, examination, and microbiological/cytological sampling, where necessary.

Hypopyon-associated with corneal disease is typically heaped up centrally and triangular in shape rather than flat. These cases should usually be investigated and treated as infectious hypopyon keratitis, although the clinician must be aware that (rarely) noninfectious causes, such as recurrent erosion syndrome, can produce similar clinical pictures (Table 3). If there is a history of trauma with organic matter or ocular surface disease, then the ophthalmologist should consider the possibility of penetrating corneal keratitis/endophthalmitis due to filamentous fungi and yeasts, respectively.

VI. Conclusions

Hypopyon^{199,200} arises as a result of inflammatory, infective, neoplastic, and therapeutic stimuli. Although there is no one unifying pathobiological process, there are certain broadly shared mechanisms of cell recruitment and tissue destruction. Identification of the causes of hypopyon enables a rational clinical approach to diagnosis, so that appropriate treatment can be instituted.

Method of Literature Search

This article was prepared using the National Library of Medicine database using the following search words: *hypopyon* and *uveitis*; *chemotaxis* and *eye*; *endophthalmitis*; *Behcet*; and *HLA-B27*. Additional sources included textbooks, such as *Ocular Infection and Immunity* (Pepose JS, Holland G, Wilhelmus K, eds) and manual searches based upon articles cited in the texts of other articles. Articles were included if they emanated from peer-review journals and excluded if they consisted of opinion without apparent evidence for the views held. In the case of non-English articles, abstracts were used where available.

References

1. ____: Criteria for diagnosis of Behcets disease. International Study Group for Behcets Disease. Lancet 335:1078-1080, 1990
2. ____: Results of the Endophthalmitis Vitrectomy Study. A

- randomized trial of immediate vitrectomy and of intravenous antibiotics for the treatment of postoperative bacterial endophthalmitis. Endophthalmitis Vitrectomy Study Group. *Arch Ophthalmol* 113:1479–96, 1995
3. Abdalla MI, el-D Bahoat N: Long-lasting remission of Behcet's disease after chlorambucil therapy. *Br J Ophthalmol* 57:706–11, 1973
 4. Abraham JC: Prevention and treatment of eye complications in leprosy. *Lepr India* 48:763–9, 1976
 5. Abramson DH, Wachtel A, Watson CW, et al: Leukemic hypopyon. *J Pediatr Ophthalmol Strabismus* 18:42–4, 1981
 6. Abu el-Asrar AM, al-Amro SA, al-Mosallam AA, al-Obeidan S: Post-traumatic endophthalmitis: causative organisms and visual outcome. *Eur J Ophthalmol* 9:21–31, 1999
 7. Affeldt JC, Flynn HW, Forster RK, et al: Microbial endophthalmitis resulting from ocular trauma. *Ophthalmology* 94:407–13, 1987
 8. Aktulga E, Altac M, Muftuoglu A, et al: A double blind study of colchicine in Behcet's disease. *Haematologica* 65:399–402, 1980
 9. al Faran MF: *Brucella melitensis* endogenous endophthalmitis. *Ophthalmologica* 201:19–22, 1990
 10. al Hazzaa SA, Tabbara KF, Gammon JA: Pink hypopyon: a sign of *Serratia marcescens* endophthalmitis. *Br J Ophthalmol* 76:764–5, 1992
 11. al-Kaff AS: Ocular brucellosis. *Int Ophthalmol Clin* 35:139–45, 1995
 12. Albert DM, Lahav M, Troczynski E, Bahr R: Black hypopyon: report of two cases. *Albrecht Von Graefes Arch Klin Exp Ophthalmol* 193:81–94, 1975
 13. Algan M, Jonon B, George JL, et al: *Listeria monocytogenes* endophthalmitis in a renal-transplant patient receiving ciclosporin. *Ophthalmologica* 201:23–7, 1990
 14. Anandi V, George JA, Thomas R, et al: Phaeohyphomycosis of the eye caused by *Exserohilum rostratum* in India. *Mycoses* 34:489–91, 1991
 15. Apple DJ, Mamalis N, Steinmetz RL, et al: Phacoanaphylactic endophthalmitis associated with extracapsular cataract extraction and posterior chamber intraocular lens. *Arch Ophthalmol* 102:1528–32, 1984
 16. Asbell P, Stenson S: Ulcerative keratitis. Survey of 30 years laboratory experience. *Arch Ophthalmol* 100:77–80, 1982
 17. Ayliffe W, Foster CS, Marcoux P, et al: Relapsing acute myeloid leukemia manifesting as hypopyon uveitis. *Am J Ophthalmol* 119:361–4, 1995
 18. Bacon AS, Frazer DG, Dart JK, et al: A review of 72 consecutive cases of *Acanthamoeba* keratitis, 1984–1992. *Eye* 7:719–25, 1993
 19. Badeeb O, Anwar M, Farwan K, et al: Leukemic infiltrate versus anterior uveitis. *Ann Ophthalmol* 24:295–8, 1992
 20. Ball SF, Lofffield K, Scharfberg J: Molteno rip-cord suture hypopyon. *Ophthalmic Surg* 21:407–11; discussion 411–2, 1990
 21. Ballen PH, Loffredo FR, Painter B: *Listeria* endophthalmitis. *Arch Ophthalmol* 97:101–2, 1979
 22. Balmer A, Gailloud C, Munier F, et al: [Unusual presentation of retinoblastoma]. *Klin Monatsbl Augenheilkd* 204:313–5, 1994
 23. Bar-Shavit R, Benezra M, Sabbah V, et al: Thrombin as a multifunctional protein: induction of cell adhesion and proliferation. *Am J Respir Cell Mol Biol* 6:123–30, 1992
 24. Barile GR, Flynn TE: Syphilis exposure in patients with uveitis. *Ophthalmology* 104:1605–9, 1997
 25. Barra C, Belfort Junior R, Abreu MT, et al: Behcet's disease in Brazil—a review of 49 cases with emphasis on ophthalmic manifestations. *Jpn J Ophthalmol* 35:339–46, 1991
 26. Beckingsale AB, Davies J, Gibson JM, Rosenthal AR: Acute anterior uveitis, ankylosing spondylitis, back pain, and HLA-B27. *Br J Ophthalmol* 68:741–5, 1984
 27. Bedrossian EH: Hypopyon keratitis: following muscle surgery. *Am J Ophthalmol* 61:1530–2, 1966
 28. Behcet H: Ueber rezidivierende Aphthose, durch ein virus verursacht am mund, am auge und an dem genitalien. *Dermatol Wochenschr* 36:1152–7, 1937
 29. Behrens-Baumann W: [Diagnosis and therapy of fungal keratitis—a review]. *Klin Monatsbl Augenheilkd* 210:A10–3, 1997
 30. Benezra D, Cohen E: Treatment and visual prognosis in Behcet's disease. *Br J Ophthalmol* 70:589–92, 1986
 31. Bentley C, Stanford M, Shilling J, et al: Macular ischaemia in posterior uveitis. *Eye* 7:411–4, 1993
 32. Bhadresra GN: Changes in the anterior segment as a presenting feature in leukaemia. *Br J Ophthalmol* 55:133–5, 1971
 33. Brewerton DA, Hart FD, Nicholls A, et al: Ankylosing spondylitis and HL-A 27. *Lancet* 1:904–7, 1973
 34. Brian GR, Treplin MC: *Listeria monocytogenes* endophthalmitis: a case report. *Aust NZ J Ophthalmol* 16:329–31, 1988
 35. Brown RH, Yang LH, Walker SD, et al: Treatment of bleb infection after glaucoma surgery. *Arch Ophthalmol* 112:57–61, 1994
 36. Bunin N, Rivera G, Goode F, Hustu HO: Ocular relapse in the anterior chamber in childhood acute lymphoblastic leukemia. *J Clin Oncol* 5:299–303, 1987
 37. Bunin NJ, Pui CH, Hustu HO, Rivera GK: Unusual extramedullary relapses in children with acute lymphoblastic leukemia. *J Pediatr* 109:665–8, 1986
 38. Calabro JJ, Eyvazzadeh C, Weber CA: Contemporary management of ankylosing spondylitis. *Compr Ther* 12:11–8, 1986
 39. Calder VL, Shaer B, Muhaya M: Increased CD4+ expression and decreased IL-10 in the anterior chamber in idiopathic uveitis. *Invest Ophthalmol Vis Sci* 40:2019–24, 1999
 40. Chee SP, Ang CL: Endogenous *Klebsiella* endophthalmitis—a case series. *Ann Acad Med Singapore* 24:473–8, 1995
 41. Ciulla TA, Beck AD, Topping TM, Baker AS: Blebitis, early endophthalmitis, and late endophthalmitis after glaucoma-filtering surgery. *Ophthalmology* 104:986–95, 1997
 42. Cohen JS, Bibler L, Tucker D: Hypopyon following laser iridotomy. *Ophthalmic Surg* 15:604–6, 1984
 43. Colmenero Castillo JD, Hernandez Marquez S, Reguera Iglesias JM, et al: Comparative trial of doxycycline plus streptomycin versus doxycycline plus rifampin for the therapy of human brucellosis. *Chemotherapy* 35:146–52, 1989
 44. Corriveau C, Easterbrook M, Payne D: Lymphoma simulating uveitis (masquerade syndrome). *Can J Ophthalmol* 21:144–9, 1986
 45. Coster DJ, Badenoch PR: Host, microbial, and pharmacological factors affecting the outcome of suppurative keratitis. *Br J Ophthalmol* 71:96–101, 1987
 46. Curto ML, D'Angelo P, Jankovic M, et al: Isolated ocular relapse in childhood acute lymphoblastic leukemia during continuing complete remission. *Haematologica* 81:47–50, 1996
 47. Curto ML, Zingone A, Acquaviva A, et al: Leukemic infiltration of the eye: results of therapy in a retrospective multicentric study. *Med Pediatr Oncol* 17:134–9, 1989
 48. Dacey MP, Valencia M, Lee MB, et al: Echographic findings in infectious endophthalmitis. *Arch Ophthalmol* 112:1325–33, 1994
 49. Dada T, Sharma N, Dada VK, Vajpayee RB: Pneumococcal keratitis after laser in situ keratomileusis. *J Cataract Refract Surg* 26:460–1, 2000
 50. D'Alessandro LP, Forster DJ, Rao NA: Anterior uveitis and hypopyon. *Trans Am Ophthalmol Soc* 89:303–9; discussion 309–11, 1991
 51. Darrell R, Wagener H, Kurland L: Epidemiology of uveitis, incidence and prevalence in a small urban community. *Arch Ophthalmol* 68:100, 1962
 52. Dawson CR, Togni B: Herpes simplex eye infections: clinical manifestations, pathogenesis and management. *Surv Ophthalmol* 21:121–35, 1976
 53. Daxecker F, Staudacher C: Ocular involvement in tuberculoid leprosy—a case report. *Ophthalmologica* 211:305–7, 1997
 54. Decker EB, Burnstine RA: Leukemic relapse presenting as acute unilateral hypopyon in acute lymphocytic leukemia. *Ann Ophthalmol* 25:346–9, 1993
 55. Deutsch D, Adler S, Teller J, Savir H: Endogenous candidal endophthalmitis. *Ann Ophthalmol* 21:260–5, 268, 1989
 56. Deutsch TA, Goldberg MF: Painless endophthalmitis after cataract surgery. *Ophthalmic Surg* 15:837–40, 1984

57. Doft BH, Barza M: Optimal management of postoperative endophthalmitis and results of the Endophthalmitis Vitrectomy Study. *Curr Opin Ophthalmol* 7:84-94, 1996
58. Doft BH, Clarkon JG, Rebell G, Forster RK: Endogenous Aspergillus endophthalmitis in drug abusers. *Arch Ophthalmol* 98:859-62, 1980
59. Doren GS, Stern GA, Driebe WT: Indications for and results of intraocular lens explantation. *J Cataract Refract Surg* 18:79-85, 1992
60. Durand L, Monnot JP, Burillon C, Assi A: Complications of radial keratotomy: eyes with keratoconus and late wound dehiscence. *Refract Corneal Surg* 8:311-4, 1992
61. Elliott D, O'Brien TP, Green WR, et al: Elevated intraocular pressure, pigment dispersion and dark hypopyon in endogenous endophthalmitis from *Listeria monocytogenes*. *Surv Ophthalmol* 37:117-24, 1992
62. Ellis GS, Pakalnis VA, Worley G, et al: *Toxocara canis* infestation. Clinical and epidemiological associations with seropositivity in kindergarten children. *Ophthalmology* 93:1032-7, 1986
63. Ells A, Clarke WN, Noel LP: Pseudohypopyon in acute myelogenous leukemia. *J Pediatr Ophthalmol Strabismus* 32:123-4, 1995
64. Espiritu CG, Gelber R, Ostler HB: Chronic anterior uveitis in leprosy: an insidious cause of blindness. *Br J Ophthalmol* 75:273-5, 1991
65. Fanous MM, Cohn RA: Propionibacterium endophthalmitis following Molteno tube repositioning. *J Glaucoma* 6:201-2, 1997
66. Farber BP, Weinbaum DL, Dummer JS: Metastatic bacterial endophthalmitis. *Arch Intern Med* 145:62-4, 1985
67. Ferry AP, Font RL: Carcinoma metastatic to the eye and orbit. I. A clinicopathologic study of 227 cases. *Arch Ophthalmol* 92:276-86, 1974
68. Ffytche TJ: Iritis in leprosy. *Trans Ophthalmol Soc UK* 101:325-7, 1981
69. Ffytche TJ: Role of iris changes as a cause of blindness in lepromatous leprosy. *Br J Ophthalmol* 65:231-9, 1981
70. Ficker L, Seal D, Wright P: Staphylococcal infection and the limbus: study of the cell-mediated immune response. *Eye* 3:190-3, 1989
71. Fonseca E, Garcia-Silva J, del Pozo J, et al: Syphilis in an HIV infected patient misdiagnosed as leprosy. *J Cutan Pathol* 26:51-4, 1999
72. Friedman AH, Bloch R, Henkind P: Hypopyon and iris necrosis in angle-closure glaucoma. Report of two cases. *Br J Ophthalmol* 56:632-5, 1972
73. Gabler B, Lohmann CP: Hypopyon after repeated transplantation of human amniotic membrane onto the corneal surface. *Ophthalmology* 107:1344-6, 2000
74. Garg P, Mathur U, Athmanathan S, Rao GN: Treatment outcome of *Moraxella* keratitis: our experience with 18 cases—a retrospective review. *Cornea* 18:176-81, 1999
75. Gills JP: Sterile hypopyon. *J Cataract Refract Surg* 18:203, 1992
76. Girard B, Brezin A, Gaumont MC, et al: [Diffuse retinoblastoma—apropos of a case]. *Bull Soc Ophthalmol Fr* 89:25-30, 1989
77. Glickman L, Schantz P, Dombroske R, Cypess R: Evaluation of serodiagnostic tests for visceral larva migrans. *Am J Trop Med Hyg* 27:492-8, 1978
78. Goldey SH, Stern GA, Oblon DJ, et al: Immunophenotypic characterization of an unusual T-cell lymphoma presenting as anterior uveitis. A clinicopathologic case report. *Arch Ophthalmol* 107:1349-53, 1989
79. Grabner G, Luger TA, Smolin G, Oppenheim JJ: Corneal epithelial cell-derived thymocyte-activating factor (CE-TAF). *Invest Ophthalmol Vis Sci* 23:757-63, 1982
80. Greenwald MJ, Wohl LG, Sell CH: Metastatic bacterial endophthalmitis: a contemporary reappraisal. *Surv Ophthalmol* 31:81-101, 1986
81. Gruenewald RL, Perry MC, Henry PH: Leukemic iritis with hypopyon. *Cancer* 44:1511-3, 1979
82. Haik BG, Dunleavy SA, Cooke C, et al: Retinoblastoma with anterior chamber extension. *Ophthalmology* 94:367-70, 1987
83. Harada Y, Kuriyagawa K, Okada K, et al: [Anterior segment of the eye and cranial nervous (II, III, VI, VII) infiltration in relapsing acute lymphoblastic leukemia (L1)]. *Rinsho Ketsueki* 35:1371-7, 1994
84. Harnett AN, Hirst A, Plowman PN: The eye in acute leukaemia. 1. Dosimetric analysis in cranial radiation prophylaxis. *Radiother Oncol* 10:195-202, 1987
85. Harnett AN, Plowman PN: The eye in acute leukaemia. 2. The management of solitary anterior chamber relapse. *Radiother Oncol* 10:203-7, 1987
86. Hatchome N, Tagami H: Hypopyon-iridocyclitis as a complication of pustular psoriasis. *J Am Acad Dermatol* 13:828-9, 1985
87. Heidemann DG, Dunn SP, Haimann M: Endophthalmitis after radial keratotomy enhancement. *J Cataract Refract Surg* 23:951-3, 1997
88. Henderly DE, Genstler AJ, Smith RE, Rao NA: Changing patterns of uveitis. *Am J Ophthalmol* 103:131-6, 1987
89. Hira SK, Patel JS, Bhat SG, et al: Clinical manifestations of secondary syphilis. *Int J Dermatol* 26:103-7, 1987
90. Hirose H, Terasaki H, Awaya S, Yasuma T: Treatment of fungal corneal ulcers with amphotericin B ointment. *Am J Ophthalmol* 124:836-8, 1997
91. Holbrook CT, Elsas FJ, Crist WM, Castleberry RP: Acute leukemia and hypopyon. *J Pediatr* 93:626-8, 1978
92. Huang SC, Soong HK, Chang JS, Liang YS: Non-tuberculous mycobacterial keratitis: a study of 22 cases. *Br J Ophthalmol* 80:962-8, 1996
93. Hussein N, Ostler H: Hansen disease, in Pepose JS, Holland GN, Wilhelmus KR (eds): *Ocular Infection and Immunity*. St Louis, Mosby, 1996, pp. 1421-9
94. Iijima S, Iwata M, Otsuka F: Psoriatic arthritis and hypopyon-iridocyclitis. Possible mechanism of the association of psoriasis and anterior uveitis. *Dermatology* 193:295-9, 1996
95. Iijima S, Iwata M, Otsuka F: Rheological analysis of peripheral blood neutrophils in a patient with cutaneous and arthropathic psoriasis accompanying hypopyon-iridocyclitis. *Australas J Dermatol* 37(Suppl 1):S40-1, 1996
96. Ionides AC, Tuft SJ, Ferguson VM, et al: Corneal infiltration after recurrent corneal epithelial erosion. *Br J Ophthalmol* 81:537-40, 1997
97. Jain S, Azar DT: Eye infections after refractive keratotomy. *J Refract Surg* 12:148-55, 1996
98. Jankovic M, Masera G, Uderzo C, et al: Recurrences of isolated leukemic hypopyon in a child with acute lymphoblastic leukemia. *Cancer* 57:380-4, 1986
99. Jewelewicz DA, Schiff WM, Brown S, Barile GR: Rifabutin-associated uveitis in an immunosuppressed pediatric patient without acquired immunodeficiency syndrome. *Am J Ophthalmol* 125:872-3, 1998
100. Johnson MW, Doft BH, Kelsey SF, et al: The Endophthalmitis Vitrectomy Study. Relationship between clinical presentation and microbiologic spectrum. *Ophthalmology* 104:261-72, 1997
101. Johnson RN, Flynn HW, Parel JM, Portugal LM: Transient hypopyon with marked anterior chamber fibrin following pars plana vitrectomy and silicone oil injection. *Arch Ophthalmol* 107:683-6, 1989
102. Joko S, Numaga J, Fujino Y, et al: [HLA and uveitis in leprosy]. *Nippon Ganka Gakkai Zasshi* 99:1181-5, 1995
103. Karesh JW, Goldman EJ, Reck K, et al: A prospective ophthalmic evaluation of patients with acute myeloid leukemia: correlation of ocular and hematologic findings. *J Clin Oncol* 7:1528-32, 1989
104. Kearney W: Leukemic hypopyon: a report of two cases. *Am J Ophthalmol* 59:495-7, 1965
105. Keat A: Reiter's syndrome and reactive arthritis in perspective. *N Engl J Med* 309:1606-15, 1983
106. Kellner H, Yu D: The pathogenetic aspects of spondyloarthropathies from the point of view of HLA-B27. *Rheumatol Int* 12:121-7, 1992
107. Kelly L, Eliason J: *Eikenella corrodens* keratitis: case report. *Br J Ophthalmol* 73:22-4, 1989
108. Kerr N, Stern GA: Bacterial keratitis associated with vernal keratoconjunctivitis. *Cornea* 11:355-9, 1992

109. Khan MA: Pathogenesis of ankylosing spondylitis: recent advances. *J Rheumatol* 20:1273–7, 1993
110. Kraushar MF, Margolis S, Morse PH, Nugent ME: Pseudohypopyon in Bests vitelliform macular dystrophy. *Am J Ophthalmol* 94:30–7, 1982
111. Kuo IC, Kapusta MA, Rao NA: Vitritis as the primary manifestation of ocular syphilis in patients with HIV infection. *Am J Ophthalmol* 125:306–11, 1998
112. Larkin G, Lightman S: Mycophenolate mofetil. A useful immunosuppressive in inflammatory eye disease. *Ophthalmology* 106:370–4, 1999
113. Lee BL, van Heuven WA: Hypopyon uveitis following pan-retinal photocoagulation. *Ophthalmic Surg Lasers* 28:505–7, 1997
114. Leonardy NJ, Rupani M, Dent G, Klintworth GK: Analysis of 135 autopsy eyes for ocular involvement in leukemia. *Am J Ophthalmol* 109:436–44, 1990
115. Lightman S, Towler H: Uveitis. London, BMJ Books, 1998
116. Lin HP, Chandran S, Tan MK, Sinniah D: Hypopyon—an early sign of leukaemic relapse. *Med Pediatr Oncol* 8:97–100, 1980
117. Lipton JH, McGowan HD, Payne DG: Ocular masquerade syndrome in lymphoid blast crisis of chronic myeloid leukemia. *Leuk Lymphoma* 20:161–3, 1995
118. Lohmann CP, Gabel VP, Heep M, et al: Listeria monocytogenes-induced endogenous endophthalmitis in an otherwise healthy individual: rapid PCR-diagnosis as the basis for effective treatment. *Eur J Ophthalmol* 9:53–7, 1999
119. Lucas D: Greers Ocular Pathology. Oxford, Blackwell Scientific Publications, 1989, ed 4
120. Macsai MS, Agarwal S: Staphylococcal endophthalmitis following cataract extraction in a patient with Darriers disease. *Cornea* 17:335–7, 1998
121. Maier G, Miller B, Freedman J, Baumgarten I: HLA antigens in acute anterior uveitis in South African blacks. *Br J Ophthalmol* 64:329–31, 1980
122. Mamo JG: The rate of visual loss in Behcets disease. *Arch Ophthalmol* 84:451–2, 1970
123. Marak GE: Phacoanaphylactic endophthalmitis. *Surv Ophthalmol* 36:325–39, 1992
124. Masera G, Carnelli V, Uderzo C, et al: Leukaemic hypopyon in acute lymphoblastic leukaemia after interruption of treatment. *Arch Dis Child* 54:73–4, 1979
125. Masi AT, Medsger TA: A new look at the epidemiology of ankylosing spondylitis and related syndromes. *Clin Orthop* 21:15–29, 1979
126. Masuda K, Nakajima A, Urayama A: Double masked trial of cyclosporine versus colchicine in Behcets disease. *Lancet* 1: 1093–6, 1989
127. Matano S, Ohta T, Nakamura S, et al: Leukemic hypopyon in acute myelogenous leukemia. *Ann Hematol* 79:455–8, 2000
128. McCoy R, White L, Tait B, Ebringer R: Serum immunoglobulins in acute anterior uveitis. *Br J Ophthalmol* 68:807–10, 1984
129. McLeod SD, Flowers CW, Lopez PF, et al: Endophthalmitis and orbital cellulitis after radial keratotomy. *Ophthalmology* 102:1902–7, 1995
130. Mead M: Evaluation and initial management of patients with ocular and adnexal trauma, in Jacobiec A (ed): Principles and Practice of Ophthalmology. Philadelphia, WB Saunders Company, 1996, pp. 3362–82
131. Meisler DM, Mandelbaum S: Propionibacterium-associated endophthalmitis after extracapsular cataract extraction. Review of reported cases. *Ophthalmology* 96:54–61, 1989
132. Michelson JB, Chisari FV: Behcets disease. *Surv Ophthalmol* 26:190–203, 1982
133. Miedziak AI, Miller MR, Rapuano CJ, et al: Risk factors in microbial keratitis leading to penetrating keratoplasty. *Ophthalmology* 106:1166–70; discussion 1171, 1999
134. Minnear FL, DeMichele MA, Leonhardt S, et al: Isoproterenol antagonizes endothelial permeability induced by thrombin and thrombin receptor peptide. *J Appl Physiol* 75:1171–9, 1993
135. Mishima S, Masuda K, Izawa Y, et al: The eighth Frederick H. Verhoeff Lecture. presented by Saiichi Mishima, MD: Behcets disease in Japan: ophthalmologic aspects. *Trans Am Ophthalmol Soc* 77:225–79, 1979
136. Miyazaki D, Inoue Y, Araki-Sasaki K, et al: Neutrophil chemotaxis induced by corneal epithelial cells after herpes simplex virus type 1 infection. *Curr Eye Res* 17:687–93, 1998.
137. Mizushima Y, Inaba G, Mimura Y, et al: Guide for the diagnosis of Behcet disease, report of the Behcet disease research committee. Japan Ministry of Health and Welfare, 1987
138. Mochizuki K, Jikihara S, Ando Y, et al: Incidence of delayed onset infection after trabeculectomy with adjunctive mitomycin C or 5-fluorouracil treatment. *Br J Ophthalmol* 81: 877–83, 1997
139. Mochizuki M, Holland GN, Akduman L, Nussenblatt R: Behcet disease, in Pepose JS, Wilhelmus KR (eds): Ocular Infection and Immunity. St. Louis, Mosby, 1996, pp. 663–75
140. Mondino BJ, Kowalski R, Ratajczak HV, et al: Rabbit model of phlyctenulosis and catarrhal infiltrates. *Arch Ophthalmol* 99:891–5, 1981
141. Mondino BJ, Rabin BS, Kessler E, et al: Corneal rings with gram-negative bacteria. *Arch Ophthalmol* 95:2222–5, 1977
142. Mukhai S: Diagnosis of ocular melanoma, in Jacobiec A (ed): Principles and Practice of Ophthalmology. Philadelphia, WB Saunders Company, 1996, pp. 3209–16
143. Mulhern MG, Condon PI, O’Keefe M: Endophthalmitis after astigmatic myopic laser in situ keratomileusis. *J Cataract Refract Surg* 23:948–50, 1997
144. Nakae K, Masaki F, Hashimoto T, et al: A nationwide epidemiological survey on Behcet disease, report 2: association of HLA B51 with clinic-epidemiological features, in Report of Behcet Disease Research Committee. Japan: Ministry of Health and Welfare; 1992
145. Newman PE, Goodman RA, Waring GO, et al: A cluster of cases of Mycobacterium chelonae keratitis associated with outpatient office procedures. *Am J Ophthalmol* 97:344–8, 1984
146. Novakovic P, Kellie SJ, Taylor D: Childhood leukaemia: relapse in the anterior segment of the eye. *Br J Ophthalmol* 73:354–9, 1989
147. Nussenblatt RB: Uveitis in Behcets disease. *Int Rev Immunol* 14:67–79, 1997
148. Nussenblatt RB, Palestine AG, Chan CC: Cyclosporine therapy for uveitis: long-term followup. *J Ocul Pharmacol* 1: 369–82, 1985
149. Nussenblatt RB, Palestine AG: Toxocara canis infection, in Nussenblatt RB (ed): Uveitis-Fundamentals and Clinical Practice. Chicago, Year Book, 1996, pp 138–43
150. Ohkoshi K, Tsiaras WG: Prognostic importance of ophthalmic manifestations in childhood leukaemia. *Br J Ophthalmol* 76:651–5, 1992
151. Ohno S, Maatsuda H: Studies of HLA antigens in Behcet disease in Japan, in Lehner T (ed): Recent Advances in Behcets Disease. London, Royal Society of Medicine Services, 1986, pp 11–6
152. Okhravi N, Towler HM, Hykin P, et al: Assessment of a standard treatment protocol on visual outcome following presumed bacterial endophthalmitis. *Br J Ophthalmol* 81: 719–25, 1997
153. Olsen TW, Sternberg P, Capone A, et al: Macular hole surgery using thrombin-activated fibrinogen and selective removal of the internal limiting membrane. *Retina* 18:322–9, 1998
154. Olsen TW, Sternberg P, Martin DF, et al: Postoperative hypopyon after intravitreal bovine thrombin for macular hole surgery. *Am J Ophthalmol* 121:575–7, 1996
155. Ormerod LD, Hertzmark E, Gomez DS, et al: Epidemiology of microbial keratitis in southern California. A multivariate analysis. *Ophthalmology* 94:1322–33, 1987
156. Ormerod LD, Ho DD, Becker LE, et al: Endophthalmitis caused by the coagulase-negative staphylococci. 1. Disease spectrum and outcome. *Ophthalmology* 100:715–23, 1993
157. Ormerod LD, Puklin JE, Giles CL: Chronic Propionibacterium acnes endophthalmitis as a cause of intermediate uveitis. *Ocul Immunol Inflamm* 5:67–8, 1997
158. Ostler HB: The immunology of Hansens disease. *Int Ophthalmol Clin* 25:117–31, 1985

159. Ozyazgan Y, Yurdakul S, Yazici H, et al: Low dose cyclosporin A versus pulsed cyclophosphamide in Behcets syndrome: a single masked trial. *Br J Ophthalmol* 76:241-3, 1992
160. Parke I, Shaver R. Toxocariasis, in Pepose JS, Wilhelmus KR (eds): *Ocular Infection and Immunity*. St Louis, Mosby, 1996, ed 1, pp 1225-35
161. Patel AS, Hemady RK, Rodrigues M, et al: Endogenous *Fusarium* endophthalmitis in a patient with acute lymphocytic leukemia. *Am J Ophthalmol* 117:363-8, 1994
162. Pfister RR, Haddox JL: A neutrophil chemoattractant is released from cellular and extracellular components of the alkali-degraded cornea and blood. *Invest Ophthalmol Vis Sci* 37:230-7, 1996
163. Pfister RR, Haddox JL, Dodson RW, Harkins LE: Alkali-burned collagen produces a locomotory and metabolic stimulant to neutrophils. *Invest Ophthalmol Vis Sci* 28:295-304, 1987
164. Pfister RR, Haddox JL, Sommers CI: Injection of chemoattractants into normal cornea: a model of inflammation after alkali injury. *Invest Ophthalmol Vis Sci* 39:1744-50, 1998
165. Pfister RR, Haddox JL, Sommers CI: Effect of synthetic metalloproteinase inhibitor or citrate on neutrophil chemotaxis and the respiratory burst. *Invest Ophthalmol Vis Sci* 38:1340-9, 1997
166. Pfister RR, Haddox JL, Sommers CI, Lam KW: Identification and synthesis of chemotactic tripeptides from alkali-degraded whole cornea. A study of N-acetyl-proline-glycine-proline and N-methyl-proline-glycine-proline. *Invest Ophthalmol Vis Sci* 36:1306-16, 1995
167. Pietruschka G: About the incidence and significance of hypopyon in anterior uveitis. *Surv Ophthalmol* 12:530-2, 1967
168. Pollard ZF, Jarrett WH, Hagler WS, et al: ELISA for diagnosis of ocular toxocariasis. *Ophthalmology* 86:743-52, 1979
169. Psilas K, Papadimitriou CS: [A case of secondary ghost cell glaucoma with pseudohypopyon after cataract extraction]. *J Fr Ophthalmol* 7:133-5, 1984
170. Pulido JS, Folberg R, Carter KD, Coonan P: *Histoplasma capsulatum* endophthalmitis after cataract extraction. *Ophthalmology* 97:217-20, 1990
171. Reed JB, Morse LS, Schwab IR: High-dose intravenous pulse methylprednisolone hemisuccinate in acute Behcet retinitis. *Am J Ophthalmol* 125:409-11, 1998
172. Reed M, Hibberd PL: Endoscopy and endophthalmitis. *N Engl J Med* 321:836, 1989
173. Richburg FA, Reidy JJ, Apple DJ, Olson RJ: Sterile hypopyon secondary to ultrasonic cleaning solution. *J Cataract Refract Surg* 12:248-51, 1986
174. Ridgway EW, Jaffe N, Walton DS: Leukemic ophthalmopathy in children. *Cancer* 38:1744-9, 1976
175. Ronday MJ, Stilma JS, Barbe RF, et al: Aetiology of uveitis in Sierra Leone, west Africa. *Br J Ophthalmol* 80:956-61, 1996
176. Roney P, Barr CC, Chun CH, Raff MJ: Endogenous aspergillus endophthalmitis. *Rev Infect Dis* 8:955-8, 1986
177. Rootman J, Gudauskas G: Treatment of ocular leukemia with local chemotherapy. *Cancer Treat Rep* 69:119-22, 1985
178. Rosenbaum JT: Characterization of uveitis associated with spondyloarthritis. *J Rheumatol* 16:792-6, 1989
179. Rosenthal AR: Ocular manifestations of leukemia. A review. *Ophthalmology* 90:899-905, 1983
180. Rosselet E, Gailloud C, Verrey F: [Retinoblastoma and hypopyon]. *Ophthalmologica* 161:139-44, 1970
181. Santoni G, Fiore C, Lupidi G, Bibbiani U: Recurring bilateral hypopyon in chronic myeloid leukemia in blastic transformation. A case report. *Graefes Arch Clin Exp Ophthalmol* 223:211-3, 1985
182. Sasaki T, Kusaba Y, Yamamoto, et al: HLA B27 and anterior uveitis in the Japanese population. *Jpn J Ophthalmol* 23:374, 1979
183. Schachat AP, Jabs DA, Graham ML, et al: Leukemic iris infiltration. *J Pediatr Ophthalmol Strabismus* 25:135-8, 1988
184. Schantz PM, Glickman LT: Toxocaral visceral larva migrans. *N Engl J Med* 298:436-9, 1978
185. Scherer WJ, Lee K: Implications of early systemic therapy on the incidence of endogenous fungal endophthalmitis. *Ophthalmology* 104:1593-8, 1997
186. Scholz R, Green WR, Baranano EC, et al: Metastatic carcinoma to the iris. Diagnosis by aqueous paracentesis and response to irradiation and chemotherapy. *Ophthalmology* 90:1524-7, 1983
187. Schwartz SD, Borchert M, Oberman A: Hypopyon keratouveitis in acute angle-closure glaucoma. *Am J Ophthalmol* 104:430-1, 1987
188. Shields JA: Ocular toxocariasis. A review. *Surv Ophthalmol* 28:361-81, 1984
189. Shields JA, Parsons HM, Shields CL, Shah P: Lesions simulating retinoblastoma. *J Pediatr Ophthalmol Strabismus* 28:338-40, 1991
190. Shimada K, Yaoita H, Shikano S: Chemotactic activity in the aqueous humour in patients with Behcets disease. *Jpn J Ophthalmol* 16:84-92, 1972
191. Shimizu T, Ehrlich GE, Inaba G, Hayashi K: Behcet disease (Behcet syndrome). *Semin Arthritis Rheum* 8:223-60, 1979
192. Shin DH: Transient hypopyon following primary or adjunct argon laser photocoagulation. *Arch Ophthalmol* 107:1566, 1989
193. Shin DH: Another hypopyon following laser iridotomy [letter]. *Ophthalmic Surg* 15:968, 1984
194. Singh D: Localized bullous separation of Descemets membrane after previous cataract surgery. *J Cataract Refract Surg* 22:147-9, 1996
195. Singh SM, Khan R, Sharma S, Chatterjee PK: Clinical and experimental mycotic corneal ulcer caused by *Aspergillus fumigatus* and the effect of oral ketoconazole in the treatment. *Mycopathologia* 106:133-41, 1989
196. Smith RE, Weiner P: Unusual presentation of phacoanaphylaxis following phacoemulsification. *Ophthalmic Surg* 7:65-8, 1976
197. Smith WS, Burke MJ, Wong KY: Hypopyon in acute lymphoblastic leukemia. *Med Pediatr Oncol* 12:258-9, 1984
198. Sobel JD, Haim S, Obedeau N, et al: Polymorphonuclear leucocyte function in Behcets disease. *J Clin Pathol* 30:250-3, 1977
199. Soloway S, Weissgold D: Images in clinical medicine. Hypopyon. *N Engl J Med* 334:1512, 1996
200. Soloway S, Weissgold D: Images in clinical medicine. Hypopyon [published erratum]. *N Engl J Med* 334:1512, 1996
201. Sprenkels SH, Van Kregten E, Feltkamp TE: IgA antibodies against *Klebsiella* and other Gram-negative bacteria in ankylosing spondylitis and acute anterior uveitis. *Clin Rheumatol* 15(Suppl 1):48-51, 1996
202. Sridhar MS, Garg P, Bansal AK, Gopinathan U: *Aspergillus flavus* keratitis after laser in situ keratomileusis. *Am J Ophthalmol* 129:802-4, 2000
203. Sridhar MS, Sharma S, Reddy MK, et al: Clinicomicrobiological review of *Nocardia* keratitis. *Cornea* 17:17-22, 1998
204. Stefansson E, Cobo LM, Carlson AN, Kesler JL: Endocapsular hypopyon: a clinical sign of localized endophthalmitis. *Ophthalmic Surg* 21:221-2, 1990
205. Tamesis RR, Foster CS: Ocular syphilis. *Ophthalmology* 97:1281-7, 1990
206. Templeton PA, Rao KC: Computed tomography of *Toxocara canis* endophthalmitis. *J Comput Tomogr* 11:99-101, 1987
207. Thomas R, Braganza A, George T, Mermoud A: Vitreous opacities in phacolytic glaucoma. *Ophthalmic Surg Lasers* 27:839-43, 1996
208. Thygeson P: Marginal corneal infiltrates and ulcers. *Trans Am Acad Ophthalmol Otolaryngol* 51:198-207, 1947
209. ouboul JP, Le Hoang P, Fontaine M, et al: [Uveitis in acquired syphilis]. *J Fr Ophthalmol* 8:321-31, 1985
210. Trocme SD, Pavan-Langston D. The spirochetes, in Albert DM, Jacobiec FA (eds): *Principles and Practice of Ophthalmology*. Philadelphia, WB Saunders, 1995, pp. 834-9
211. Trojan HJ, Schaller KF, Merschmann W: [Eye involvement in leprosy. A study in Togo, West Africa]. *Klin Monatsbl Augenheilkd* 185:235-42, 1984

212. Trudeau M, Shepherd FA, Blackstein ME, et al: Intraocular lymphoma: report of three cases and review of the literature. *Am J Clin Oncol* 11:126–30, 1988
213. Uchio E, Hatano H, Mitsui K, et al: A retrospective study of herpes simplex keratitis over the last 30 years. *Jpn J Ophthalmol* 38:196–201, 1994
214. Uniat LM, Olk RJ, Kenneally CZ, Windsor CE: Endophthalmitis after strabismus surgery with a good visual result. *Ophthalmic Surg* 19:42–3, 1988
215. Verbraeken H: Diagnostic vitrectomy and chronic uveitis. *Graefes Arch Clin Exp Ophthalmol* 234(Suppl 1):S2–7, 1996
216. Vine AK, Johnson MW: Thrombin in the management of full thickness macular holes. *Retina* 16:474–8, 1996
217. Watt PJ: Pathogenic mechanisms of organisms virulent to the eye. *Trans Ophthalmol Soc UK* 105:26–31, 1986
218. Wehrly SR, Manning FJ, Proia AD, et al: Cytomegalovirus keratitis after penetrating keratoplasty. *Cornea* 14:628–33, 1995
219. Weisenthal R, Frayer WC, Nichols CW, Eagle RC: Bilateral ocular disease as the initial presentation of malignant lymphoma. *Br J Ophthalmol* 72:248–52, 1988
220. White L, McCoy R, Tait B, Ebringer R: A search for gram-negative enteric micro-organisms in acute anterior uveitis: association of klebsiella with recent onset of disease, HLA-B27, and B7 CREG. *Br J Ophthalmol* 68:750–5, 1984
221. Wilhelmus K, et al: Syphilis, in Pepose JS, Holland GN, Wilhelmus KR (eds): *Ocular Infection and Immunity*. St Louis, Mosby, 1996, pp. 1437–66
222. Wilhelmus K. Bacterial keratitis, in Pepose JS, Wilhelmus KR (eds): *Ocular Infection and Immunity*. St Louis, Mosby; 1996, pp 981–93
223. Wilhelmus KR: The pathogenesis of endophthalmitis. *Int Ophthalmol Clin* 27:74–81, 1987
224. Wong JS, Chan TK, Lee HM, Chee SP: Endogenous bacterial endophthalmitis: an east Asian experience and a reappraisal of a severe ocular affliction. *Ophthalmology* 107:1483–91, 2000
225. Wormald RP, Harper JI: Bilateral black hypopyon in a patient with self-healing cutaneous malignant melanoma. *Br J Ophthalmol* 67:231–5, 1983
226. Wright P, Warhurst D, Jones BR: Acanthamoeba keratitis successfully treated medically. *Br J Ophthalmol* 69:778–82, 1985
227. Yanoff M, Fine BS: *Ocular Pathology*. St Louis, Mosby, 1996
228. Yazici H, Pazarli H, Barnes CG, et al: A controlled trial of azathioprine in Behcet's syndrome. *N Engl J Med* 322:281–5, 1990
229. Yorston D, Foster A: Traditional eye medicines and corneal ulceration in Tanzania. *J Trop Med Hyg* 97:211–4, 1994
230. Yurdakul S, Gunaydin I, Tuzun Y, et al: The prevalence of Behcet's syndrome in a rural area in northern Turkey. *J Rheumatol* 15:820–2, 1988
231. Zakka KA, Yee RD, Shorr N, et al: Leukemic iris infiltration. *Am J Ophthalmol* 89:204–9, 1980
232. Zambrano W, Flynn HW, Pflugfelder SC, et al: Management options for *Propionibacterium acnes* endophthalmitis. *Ophthalmology* 96:1100–5, 1989
233. Zamiri P, Boyd S, Lightman S: Uveitis in the elderly—is it easy to identify the masquerade? *Br J Ophthalmol* 81:827–31, 1997
234. Zierhut M, Kreissig I, Pickert A: Panuveitis with positive se-

rological tests for syphilis and Lyme disease. *J Clin Neuroophthalmol* 9:71–5; discussion 76–8, 1989

235. Zygulska-Mach H, Krukar-Baster K, Ziobrowski S: Ocular toxocariasis in children and youth. *Doc Ophthalmol* 84:145–54, 1993

Outline

- I. Definitions
- II. Pathology
- III. Pathogenesis
- IV. Disorders causing hypopyon
 - A. Noninfectious disease
 1. HLA-B27-associated uveitis
 2. Behcet's disease
 - B. Iatrogenic causes
 1. Medical agents
 - a. Rifabutin
 - b. Traditional eye medicines
 2. Surgical causes
 - a. Lens-associated uveitis
 - b. Retained surgical products
 - c. Laser
 - C. Infectious diseases
 1. Exogenous disease
 - a. Hypopyon following cataract surgery
 - b. Hypopyon following other surgery
 - c. Trauma
 2. Endogenous diseases
 - a. Endogenous endophthalmitis
 - b. Toxocariasis
 - c. Syphilis
 - d. Hansen disease
 - e. Brucellosis
 - f. Herpes simplex virus infection
 - D. Neoplasia/masquerade conditions
 1. Leukemia
 2. Lymphoma
 3. Retinoblastoma
 4. Other tumors
 - E. Corneal disorders
 1. Microbial keratitis
 2. Noninfectious corneal injuries
- V. Clinical approach to hypopyon
 - A. Associated systemic conditions
 - B. Past ophthalmic history
- VI. Conclusion

The authors have no proprietary or commercial interest in any concept or product discussed in this article.

Reprint address: Professor S. Lightman, Department of Clinical Ophthalmology, Institute of Ophthalmology, Moorfields Eye Hospital, City Rd, London EC1V 2PD, United Kingdom. Email: s.lightman@ucl.ac.uk